



Histological Study of the Effect of Aluminum in Testes of Albino Mice

Abdul-Hadi Abbas Hadi

Department of Biology, Faculty of Science, University of Kufa, Najaf, Iraq

ARTICLE INFO

Received: 20.06.2013

Revised: 20.07.2013

Accepted: 10.08.2013

Publish online: 15.08.2013

*Corresponding author:

Email address:

abdulhadi.alibraheemi@uokufa.edu.iq

Abstract

Aluminum is widely distributed and constitutes approximately 8.8% of the earth's crust and considers as potential toxin in the environment, especially when present in high concentrations. This study sought to study the effects of subcutaneous injection of aluminum chloride on the histological structure of testes of the albino mice and comprises the effect at concentrations of 80, 160, 240, 320, and 400 mg/kg body weight. Increasing degree of damage of testicular tissue in correlation with the number and the amount of doses of aluminum chloride such as diffusion of oedematous fluid in the tissues, congestion of blood vessels, pyknosis of nuclei and an increase in the number of giant cells were the prominent histopathological changes.

To cite this article: Abdul-Hadi Abbas Hadi (2013). Histological Study of the Effect of Aluminum in Testes of Albino Mice. Mirror of Research in Veterinary Sciences and animals. MRSVA 2 (3), 51-57. DOI: [10.22428/mrvsa.2307-8073.2013.00236.x](https://doi.org/10.22428/mrvsa.2307-8073.2013.00236.x)

Keywords: Aluminum toxicity, testes, histopathology, mice.

Introduction

Aluminum is the most abundant metal and the third most abundant element, after oxygen and silicon, in the earth's crust. It is widely distributed and constitutes approximately 8.8% of the earth's crust (ATSDR, 2008). It normally occurs in vegetable and animal tissues, and is present in raw untreated water (Wills and Savory, 1988).

In 1886, the first practical and economic process for producing aluminum metal was discovered. Cookware was the first commercial application for the new metal. Shortly thereafter, claims of various adverse health effects from exposure to aluminum began to appear, but they did not originate from nor were they supported by scientific literature (Epstein, 1990). In recent years, the biological effects of aluminum have gained in importance, since this element constitutes a potential toxin in the environment.

For many years it has been recognized that aluminum is toxic to aquatic organisms (Muniz & Leivstad, 1980). When aluminum becomes available to organisms through

acidification of surface waters, it is toxic to fish (Driscoll *et al.*, 1980). The main effects of aluminum exposure in fish are respiratory and ion regulatory disturbances (Gensemer & Playle, 1999).

There are several evidences suggesting that the accumulation of aluminum causes toxic effects in mammals (Cannata and Domingo, 1989). Human exposure to aluminum is a consequence of the element presence in food, drinking water, air as well as its use in preparations administered therapeutically in large quantities as antacids, buffered aspirin and others (Epstein, 1990). The clinical toxic manifestations associated with an increased body burden of aluminum include Alzheimer disease, encephalopathy, osteodystrophy, and anemia. The aspects of aluminum toxicity have been reviewed by Hewitt *et al.*, (1990).

Studies concerning the histopathological effect of aluminum on the testes are scarce. This study designed to assess the effect of different levels of aluminum chloride on the testes of mice as a part of the male reproductive system.

Materials and Methods

The experimental animals were obtained from the animal house of College of Science, Baghdad University/ Iraq. Sexually mature male albino mice (Swiss strain), weighing 25 gm, were housed in plastic cages in a room with controlled temperature (20 -25 C°) and light cycle (14 h light and 10 h dark). Food and tap water were available *ad libitum*. The animals were divided into six groups (25 mice each). The first five groups were injected subcutaneously with aluminum chloride (AlCl₃) at different concentrations (80, 160, 240, 320 and 400 mg/kg body weight), while animals of the remaining groups were injected with normal physiological saline and served as control. Each treated group was divided into five subgroups (5 mice each) and the treatments were repeated 1,2,3,4 and 5 times every other day on each subgroup.

The animals were euthanized 48 hours after the last treatment. The testes were dissected out and fixed in Bouin's fluid. Six micrometer paraffin sections were made and stained with haematoxylin and eosin for routine histological examination (Humason, 1967). Sections from testes of each animal were investigated histologically in order to evaluate the histological features and severity and degrees of the structural changes. Micrographs were done by camera mounted microscope (Polyvar compound photomicroscope).

Results

The testes of control animals, displayed the histological features of the normal testes (Figure 1). Each testis is enclosed in a thick, connective tissue capsule. This connective tissue surrounds and supports the seminiferous tubules. These tubules are lined with a germinal epithelium, which consists of two types of cells, the spermatogenic cells and supportive cells (Sertoli cells). These cells rest on the basement membrane of the seminiferous tubules. Located in the interstitial connective tissue numerous blood vessels and clusters of interstitial cells (Leydig cells).

Various histological features were seen in the testis sections prepared from the treatment groups. All testes sections revealed presence of oedematous fluid in the tissues, dilatation and congestion of blood vessels, irregularity of germ cell layers, pyknosis of nuclei, giant cells and degeneration with clear necrotic debris in tubules. The changes were more severe and prominent in the mice treated with high concentration of aluminum chloride and showed inhibition of spermatogenesis and complete absence of sperms in the lumen of the tubules (Figures 2-6).

Discussion

The present study was performed to investigate the possible effect of aluminum chloride on testes of mice. Prominent histological changes were observed in the testes of aluminum-treated mice. However, the severity of histopathological changes was related to the duration, number of doses, and concentrations of aluminum chloride, which probably indicate the possible accumulation effect of this metal.

Previous studies demonstrated that aluminum accumulate in the testes of rat (Ondreicka *et al.*, 1966). Another study showed that subcutaneous injection of rabbits with aluminum chloride daily for 28 days was associated with significant accumulation of aluminum in bone, renal cortex, renal medulla, liver, testes, skeletal muscle, heart, brain white matter, hippocampus, and plasma (Du Val *et al.*, 1986).

Gue *et al.*, (2005) reported that the increase in the accumulation of the aluminum in the testes led to significant decrease in the weights of the reproductive organs in the experimental animals that treated with aluminum.

As an element, aluminum is always found attached to other chemicals and these affinities can change within the body. In living organisms, aluminum is believed to exist in four different forms: as free ions, as low-molecular-weight complexes, as physically bound macromolecular complexes, and as covalently bound macromolecular complexes (Ganrot, 1986).

The aluminum causes dilatation and congestion of blood vessels. This congestion is attributed to hypertension in the surface blood vessels (Aoki and Hoffer, 1978). The important effect of the metal on the cell membrane is the inhibition of ion-transporting systems and the resultant disturbance in fluid movements (Rothstein, 1959). Therefore, aluminum probably interferes with the cellular membranes of blood vessels causing infiltration of a large amount of fluids and serum albumin to the interstitial spaces of testes. The Shrunken tubules and reduction in diameters was related to a notable increase in interstitial spaces between the tubules which appeared full of oedematous fluid as a result of cellular degeneration in these tubules. Many other studies agree with these findings (Kamboj and Kar, 1964; Hadi and Alwachi, 1995).

The results of the study demonstrated clearly the destructive effects of aluminum on spermatogenic cells, since accumulation of aluminum in testes lead to spermatogenic arrest and destruction of sperms particularly at the high concentrations. Similar results were observed in testes of mice treated with aluminum. Kamboj & Kar, (1964) reported that in rats, the testes were focally necrosed and spermatozoa were destroyed after intratesticular injection of aluminum sulfate. An intermediate-duration oral study in male rats found that sperm count was decreased following exposure to 2.5 mg Al/kg/day as aluminum chloride for 6–12 months (Krasovskii *et al.*, 1979).

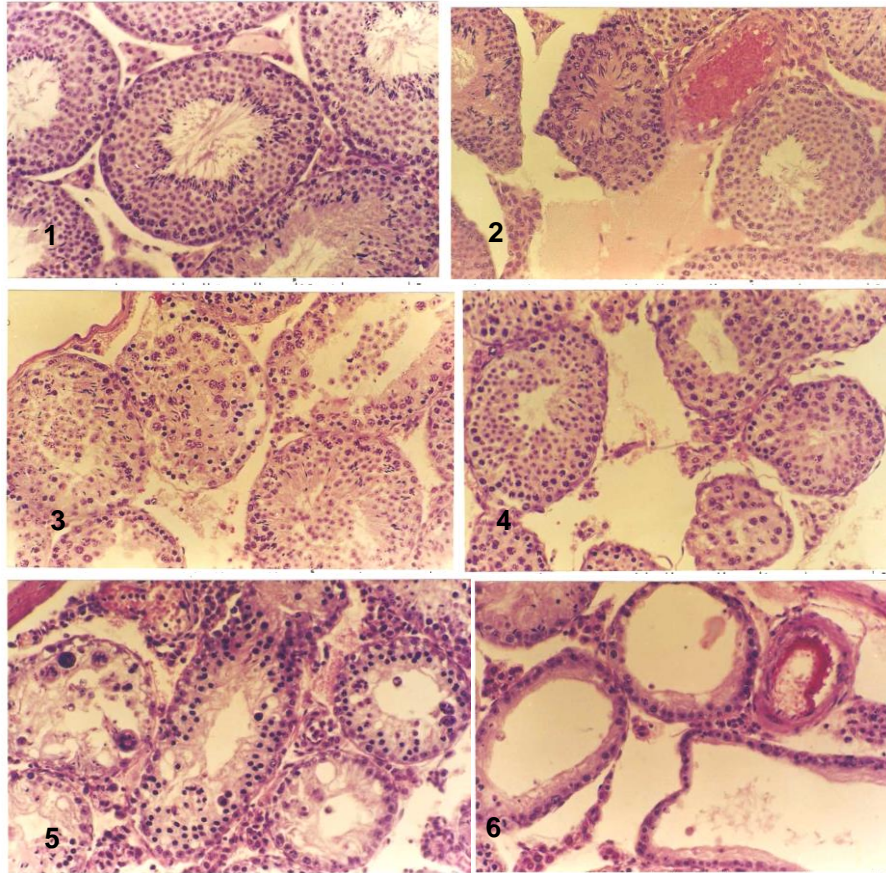


Fig. 1. Section in the testis of nontreated mice showing the normal structure of testis. X156.

Fig. 2. Section in the testis of mice treated with one dose of 80 mg/kg AlCl_3 showing moderate congestion of blood vessel and infiltration of oedematous fluid in the interstitial space. X156.

Fig. 3. Section in the testis of mice treated with two doses of 160 mg/kg AlCl_3 showing pyknotic nuclei of spermatogonia with necrotic debris in seminiferous tubules. X156.

Fig. 4. Section in the testis of mice treated with three doses of 240 mg/kg AlCl_3 showing shrunken tubules, lifting of basement membrane, and presence of oedematous fluid. X156.

Fig. 5. Section in the testis of mice treated with four doses of 320 mg/kg AlCl_3 showing pyknosis of nuclei, severe damage in the tubule architecture, and inhibition of spermiogenesis and complete absence of sperms in the lumen of tubules, and presence the giant cells. X156.

Fig. 6. Section in the testis of mice treated with five doses of 400 mg/kg AlCl_3 showing dilatation and obvious congestion of blood vessels, severe degeneration in the germinal epithelium lining of tubules, and deformation in architecture of tubules. X156.

Necrosis of spermatogenic cells were observed in the testes of male mice treated with 100 and 200 mg/kg/day of aluminum nitrate (Llobet *et al.*, 1995). According to Gue *et al.*, (2005), the spermatogenetic impairment within the seminiferous tubules was apparent when aluminum chloride administered subcutaneously to adult male mice.

Kutlubay *et al.* (2007) noted in the aluminum -treated rats, the germinal epithelium of the seminiferous tubules was thinner in places and spermatids were almost absent; sperm numbers were low and there were no sperm in the lumen. Similarly, in the aluminum chloride-treated rats, histopathological examinations revealed apparent alterations in the testes, where it induced marked lesions in seminiferous tubules (Yousef and Salama, 2009). Moreover, the relatively mild effect of aluminum on the spermatogenic epithelium of mice may be due to a disturbance in pituitary gonadotrophic activity (Kamboj and Kar, 1964). Aluminum exerted a significant adverse effect on the steroidogenesis, as well as increased production of nitric oxide, induced by excessive aluminum, might inhibit testosterone levels (Guo *et al.*, 2001). Histopathological changes observed in the testes of rats treated with aluminum included variable degree of cellular degeneration ranging from vacuolation to complete focal destruction. Aluminum might play an important role in several pathologies, which could be related to its interactions with cell membranes (Suwalsky, 2004). Aluminum alters physical properties of membrane lipids (Viestra and Haug, 1978). It is possible that the metal acted primarily on the cell membrane causing its dissolution and eventually on the intracellular constituents to convert them into debris (Kamboj and Kar, 1964). Aluminum interferes with important metabolic processes in the cells (Rosseland, 1990). It may affect second messenger systems and calcium availability (Birchall and Chappell, 1988). At the same time, the toxic influence of the metal is against the enzyme systems (Passow *et al.*, 1961). Based on this information, Yousef, (2004) indicated that the aluminum chloride affect the activities of some enzymes in rabbit plasma, liver, brain, testes and kidney. They also stated that aluminum binds to DNA phosphate and nitrogenous bases in the nucleus (karlik, *et al.*, 1980), irreversibly binds to cell nucleus components (Crapper McLachlan, 1989), and decreases cell division (Gelfant, 1963). In conclusion, treated male mice with aluminum chloride led to destroyed of spermatogenic cells, the destruction effects were severe in the higher treatment concentration due the accumulation of aluminum in testes that's led to spermatogenic arrest and destruction of sperms.

References

- Aoki A and Hoffer AP. (1978).** Reexamination of the lesions in rat caused by cadmium. *Bilo. Reprod.* 18: 579-591.
- ATSDR. (2008).** Draft toxicological profile for aluminum. Atlanta, US Department of Health and Human Services, Public Health Service, Agency for Toxic Substances and Disease Registry.
- Birchall JD, and Chappell JS. (1988).** The chemistry of aluminum and silicon in relation to Alzheimer's disease. *Clin. Chem.* 34:265-267.
- Cannata JB and Domingo, J.L. (1989).** Aluminum toxicity in mammals: A mini review. *Veterinary and human toxicology.* 31: (6) 577-583.
- Crapper McLachlan DR. (1989).** Aluminum neurotoxicity: Criteria for assigning a role in Alzheimer's disease. In: Lewis TE, ed. *Environmental chemistry and toxicology of aluminum.* Chelsea, MI: Lewis Publishers, Inc., p. 299-315.

Du Val G, Grubb BR, and Bently PJ. (1986). Tissue distribution of subcutaneously administered aluminum chloride in weanling rabbits. *J Toxicol. Environ. Health.* 19:97-104.

Driscoll CT, Baker JP, Bisigni JJ, and Schofield CL. (1980). Effects of aluminum speciation on fish in dilute acidified waters. *Nature.* 284: 161-164.

Epstein SG. (1990). Human exposure to aluminum. *Environmental geochemistry and health.* 12: 65-70.

Ganrot PO. 1986. Metabolism and possible health effects of aluminum. *Environ. Health. Perspect.* 65:363-441.

Gelfant S. (1963). Inhibition of cell division- a critical experimental analysis. *Rev. Cytol.* 14: 249-254.

Gensemer RW. and Playle, R.C. (1999). The bioavailability and toxicity of aluminum in aquatic environments. *Crit. Rev. Environ. Sci. Technol.* 29: 315-450.

Guo C, Huang C, Chen S, and Hsu, G. (2001). Serum and testicular testosterone and nitric oxide products in aluminum-treated mice. *Environmental toxicology and pharmacology.* 10: (1-2) 53-60.

Guo, C, Lu Y, and Hsu G. (2005). The influence of aluminum on male reproduction and offspring in mice. *Environmental toxicology and pharmacology.* 20: (1) 135-141.

Hadi AA. and Alwachi SN. (1995). Effect of aluminum chloride on mice spermatogenesis. *Iraqi J. Scie.* 36: (1) 1-12.

Hewitt CD, Savory J, and Wills MR. (1990). Aspects of aluminum toxicity. *Clinics in laboratory medicine.* 10: (2) 403-422.

Humason GL. (1967). *Animal tissue techniques.* Freeman, W.H. and Co. Sanfrancisco.

Kamboj VP and Kar AD. (1964). Antitesticular effect of metallic rare earth salts. *J. Reprod. Fertil.* 7: 21-28.

Karlik SJ, Eichhom GL, and Crapper DR. (1980). Interactions of aluminum species with deoxyribonucleic acid. *Biochemistry.* 19: 5991-5998.

Krasovskii GN, Vasukovich LY, and Chariev OG. (1979). Experimental study of biological effects of lead and aluminum following oral administration. *Environ. Health. Perspect.* 30:47-51.

Kutlubay R, Oguz EO, Sinik Z, Tuncay OL, Can B, and Güven MC. (2007). Vitamin E protection from testicular damage caused by intraperitoneal aluminum. International journal of toxicology. 26: (4) 297-306.

Llobet JM, Colomina MT, Sirvent JJ, Domingo JL, and Corbella J. (1995). Reproductive toxicology of aluminum in male mice. Toxicological sciences. 25: (1) 45-51.

Muniz IP, and Leivstad H. (1980). Acidification-effects on freshwater fish. In: Drablos D, Tollan A, editors. Proceedings of the International Conference on Ecological Impact of Acid Precipitation. Sandfjord, Norway. p. 222 -223.

Ondreika R, Ginter E and Kortus J. (1966). Chronic toxicity of aluminum in rats and mice and its effect on phosphorus metabolism. British journal of industrial medicine. 23: 305-312.

Passow H, Rothstein A, and Clarkson TW. (1961). The general pharmacology of the heavy metals. Pharmacol. Rev. 13: 185-224.

Rosseland BO, Eldhust TD, and Staurnes M. (1990). Environmental effects of aluminum. Environmental geochemistry and health.12: 27.

Rothstein A. (1959). Cell membrane as site of action of heavy metals. Fed. Proc. 18: 1026-1035.

Suwalsky M, Norris B, Villena F, Cuevas F, Sotomayor P, and Zatta, P. (2004). Aluminum fluoride affects the structure and functions of cell membranes. Food and chemical toxicology. 42: (6) 925-933.

Viestra R and Haug A. (1978). The effect of aluminum 3+ on the physical properties of membranes in *Thermoplasma acidophilum*. Biochem.Biophys. Res. Commun. 84: 134-144.

Wills MR and Savory J. (1988). Aluminum toxicity and chronic renal failure. In: H. Sigel and A. Sigel, metal ions in biological systems. Vol. 24. Aluminum and its role in biology. Marcel Dekker, Inc. New York.

Yousef MI. and Salama Af.(2009). Propolis protection from reproductive toxicity caused by aluminum chloride in male rats. Food and chemical toxicology. 47: (6) 1168-1175.

Yousef MI. (2004). Aluminum-induced changes in hemato-biochemical parameters, lipid peroxidation and enzyme activities of male rabbits: protective role of ascorbic acid. Toxicology. 199: (1) 47-57.