



## Lumpy Skin disease: Review of literature

K. A. Al-Salihi

<sup>1</sup>BSC, MSC, Ph.D. in Veterinary Medicine and Pathology / Faculty of Veterinary Medicine / the University of Nottingham / UK

### ARTICLE INFO

**Received:** 05.10.2014

**Revised:** 25. 10.2014

**Accepted:** 07.11.2014

**Publish online:** 09. 11.2014

**\*Corresponding author:**

**Email address:**

[kama\\_akool18@yahoo.co.uk](mailto:kama_akool18@yahoo.co.uk)

### Abstract

**Lumpy skin disease (LSD)** causes huge economic losses in the livestock industry. It is caused by Lumpy skin disease virus

(LSDV), which belongs to the family *Poxviridae*, with the *Neethling strain* the prototype. LSDV belongs to the genus *Capripoxvirus* that includes sheep pox virus and goat pox virus. LSD is an enzootic infectious, eruptive and seldom fatal disease of cattle characterised by nodules on the skin. Cattle and water buffalo are the only animal species affected, with high morbidity rate, but low mortality, however, death rates are higher among calves. LSD causes loss of milk and beef production, abortions in females and sterility in males. The original foci of LSD are from Zambia in 1929. LSD is considered as an endemic disease in the African continent. However, the disease has been moved beyond Africa in 1984. It is reported in Madagascar and some countries in the Arab Gulf Peninsula and Middle East. Recently, the disease is reported in LSD free countries (Jordan, Syria, Lebanon, Turkey, Iran and Iraq) with potential economic loss to the livestock industry. This review article intends to discuss the LSD in the light of the recent situation raises concerns the spreading of the disease in LSD free countries.

**To cite this article:** K. A. Al-Salihi, (2014). Lumpy Skin disease: Review of literature. *MRSVA*. 3 (3), 6-23.

DOI: [10.22428/mrvsa.2307-8073.2014.00332.x](https://doi.org/10.22428/mrvsa.2307-8073.2014.00332.x)

**Keywords:** Lumpy skin disease, cow, knopvelsiekte, Middle East.

## Introduction

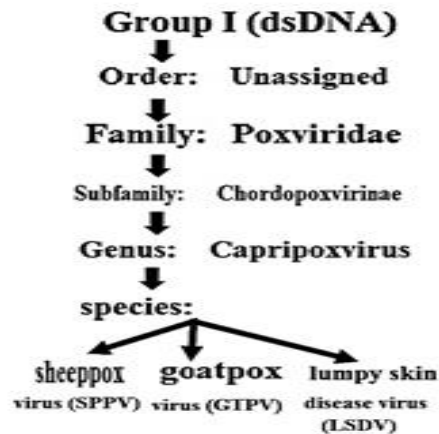
Lumpy skin disease (LSD, Pseudo-urticaria, Neethling virus disease, exanthema nodularis bovis, and knopvelsiekte) is an infectious disease. It is caused by a virus (LSDV) in the family *Poxviridae*, genus *Capripoxvirus*. It is closely related antigenically to sheep and goat pox virus. However, these viruses cannot be differentiated using routine serological test (Alexander *et al.*, 1957). LSD is a disease of cattle and water buffalo. It is a vector-borne disease transmitted by different biting and biting blood-feeding arthropods. LSD Causes considerable economic losses due to emaciation, damage to hides, infertility, mastitis, loss of milk production, and mortality of up to 20%. The severity of clinical signs of LSD depends on the strain of capripoxvirus and

the host cattle breed (Anonymous, 1988). Until 1989, Lumpy skin disease is limited to African continent. However, the disease is moved outside Africa to Madagascar and the Middle East and causes serious economic loss to the livestock industry. The incubation period in the field is believed to be two to five weeks, and lesions first appear at the inoculation site in 4 to 20 days. Fever is the initial sign that is followed within two days by the development of nodules on the skin and mucous membranes (Tuppurainen and Oura, 2012; Brenner *et al.*, 2006). A diagnosis of LSD is building upon the basis of the typical clinical patterns (morbidity and mortality). A confirmed diagnosis is based on transmission electron microscopic (TEM), immunoperoxidase (IMP) staining, antigen-trapping enzyme-linked immunosorbent assay (ELISA) and a polymerase chain reaction (PCR) test. There is no specific treatment for LSD. However, supportive treatment should be given to infected animals to relieve clinical signs and to control all secondary complications. Immunization of the susceptible animals is the effective methods to control the disease in South Africa, and the effective vaccines are produced from the Neethling strain virus (Ayelet *et al.*, 2014).

### **The Causative Organism**

The genus Capripoxvirus of the family Poxviridae is the causative agent of Lumpy skin disease. Lumpy skin disease virus (LSDV) is closely related antigenically to sheep and goat poxviruses (Woods, 1988). Although these three viruses are distinct, they cannot be differentiated with routine serological tests (Figure. 1). LSDV is susceptible to 55°C/2 hours and 65°C/30 minutes. It can be recovered from skin nodules and kept at –80 °C for 10 years. The infected tissue culture fluid can be stored at 4°C for 6 months. The virus is susceptible to highly alkaline or acid pH. However, there is no significant reduction in titre when held at pH 6.6–8.6 for 5 days at 37°C. LSDV is susceptible to ether (20%), chloroform, formalin (1%), and some detergents, e.g. sodium dodecyl sulphate. In addition, it is also susceptible to phenol (2% /15 minutes), sodium hypochlorite (2–3%), iodine compounds (1:33 dilution), Virkon® (2%) and quaternary ammonium compounds (0.5%). LSDV has remarkably stable, surviving for long periods at ambient temperature, especially in dried scabs. LSDV is very resistant to inactivation. It is surviving in necrotic skin nodules for up to 33 days or longer, desiccated crusts for up to 35 days and at least 18 days in air-dried hides. It can remain viable for long periods in the environment. Meanwhile, the virus is susceptible to sunlight and detergents containing lipid solvents, while, in dark environmental conditions, such as contaminated animal sheds, it can persist for many months. The genomic sequence of LSDV is identified (Tulman *et al.*, 2001). The LSDV genome (151-kbp) consists of a central coding region bounded by identical 2.4 kbp-inverted terminal repeats and contains 156 putative genes. However, the chordopoxviruses of other genera reveals 146 conserved genes, which encode proteins involved in transcription and mRNA biogenesis, nucleotide metabolism, DNA replication, protein processing, virion structure and assembly, and viral virulence and host range. LSDV genes share a high degree of collinearity and amino acid identity (average of 65%) of its genomic region with genes of other known mammalian poxviruses, particularly suipoxvirus, yatapoxvirus, and leporipoxviruses. The collinearity is disrupted and poxvirus homologues are either absent or share a lower percentage of amino acid identity (average of 43%) in the

terminal regions. Although LSDV resembles leporipoxviruses in gene content and organization, it also contains homologues of interleukin-10 (IL-10), IL-1 binding proteins, G protein-coupled CC chemokine receptor, and epidermal growth factor-like protein which are found in other poxvirus genera. LSDV is closely related to other members of the Chordopoxvirinae, it contains a unique complement of genes responsible for viral host range and virulence. The complete genome sequences of several capripoxviruses, including LSDV (Tulman *et al.*, 2001), sheep poxvirus and goat poxvirus (Tulman *et al.*, 2002), have been published.



**Figure 1.** Classification of Lumpy skin disease virus

## History of lumpy skin disease

The first description of the clinical signs of LSD was in 1929 in Zambia (formerly Northern Rhodesia) (Morris, 1931). In the beginning, LSD signs were considered to be the consequence either of poisoning or a hypersensitivity to insect bites. Same clinical signs were occurred in Botswana, Zimbabwe and the Republic of South Africa between 1943 and 1945, where the infectious nature of the disease was recognized in these outbreaks. In South Africa, LSD occurred as a panzootic, which affected eight million cattle. The disease continuous until 1949, and generate massive economic losses (Thomas and Mare, 1945; Von Backstrom, 1945; Diesel, 1949). In 1957, LSD was identified in East Africa in Kenya. In 1972, the disease was reported in Sudan (Ali and Obeid, 1977) and West Africa in 1974. While, it was spreading into Somalia in 1983 (Davies, 1991 a and b).

The disease has continuous to spread over most of African continent in a series of epizootics as previously recorded by Davies, (1991 b) and House, (1990). In 2001, LSD was reported in Mauritius, Mozambique and Senegal.

Nowadays, LSD occurs in most of African continent (except Libya, Algeria, Morocco and Tunisia) (Tuppurainen and Oura, 2012). Until 1980s (From 1929 to 1984) the disease was limited to countries in Sub-Saharan African continent, albeit it's probable to move beyond this range had been proposed (Davies, 1981).

In the Middle East, the outbreaks of the LSD, were reported in Oman in 1984 and 2009 (House *et al.*, 1990; Kumar, 2011; Tageldin, 2014). Kuwait in 1986 and 1991, Egypt in 1988 and 2006 (Ali *et al.*, 1990; House *et al.*, 1990; Davies, 1991a; Fayez and Ahmed,

2011; Ali and Amina, 2013), Israel in 1989 and 2006 (Shimshony, 1989; APHIS, 2006; Shimshony and Economides, 2006), Bahrain in 1993 and 2002-2003, Yemen, United Arab Emirates in 2000 and the West Bank also reported LSD invasion (Shimshony and Economides, 2006; Kumar 2011; Sherrylin *et al.*, 2013). In Oman, LSD was re-emerged once again in 2009 in a farm population of 3200 Holstein animals with 9 high morbidity and mortality rates 30-45 % and 12% respectively (Tageldin *et al.*, 2014). In Egypt, Suez Governorate, the LSD was reported in May 1988 (Ali *et al.*, 1990). The disease was arrived in Egypt with cattle imported from-Africa and kept at the local quarantine station. It spread locally in the summer of 1988 and apparently overwintered with little or no manifestation of clinical disease. Twenty-two out of twenty-six Egyptian governorates were affected with diseases, then the disease reappeared in the summer of 1989 and continuous for five to six months. This epizootic showed low morbidity rate (2%) due to the vaccination procedure that included nearly two million cattle with a sheep pox vaccine. However, approximately 1449 animals died. In the summer of 2006, in one farm with a total of 30 cases in dairy cows. LSD outbreak was re-emerged once again in several Egyptian governorates, where all age groups and both sex of Egyptian cattle were infected with severe and serious complications. (Fayez and Ahmed, 2011; Ali and Amina, 2013). In Israel, the LSD was reported in 1989. This outbreak was subsequently disposed of by the slaughter of all infected cattle as well as contacts. In addition, ring vaccination with a sheep pox strain was carried out around the focus area which led to limit the distribution of the disease.

One of the recent outbreaks of LSD in African continent were occurred in central Ethiopia in 2007 to 2011. These outbreaks were described as active. It was investigated in four districts: Adama, Wenji, Mojo and Welenchiti. The totally 1,675 outbreaks were reported over 5 years period from 2007 to 2011, with 62,176 cases and 4,372 deaths. The Oromia represented the highest numbers of outbreaks (1,066), followed by Amhara (365) and the Southern Nations, Nationalities and People's Region (123). The 2010 were reported the highest number of outbreaks that were frequently seen between September and December. The morbidity and mortality rates were 13.61% (296) and 4.97 % respectively (Ayelet *et al.*, 2014).

Syria, Lebanon and Jordan are joined LSD affected countries in 2012 and 2013. The disease has been reported in Turkey in October 2013, Iran and Iraq in 2014 (Figure. 2) (Sherrylin *et al.*, 2013; Lumpy skin disease, Iraq 2015).

In Jordan, LSD was reported as emerging disease. The outbreak started in mid-April, 2013. Two adult dairy cattle in Bani Kenanah district, Irbid governorate, on the Jordanian border of Israel and Syria, were developed clinical signs suggestive of LSD and confirmed as positive by PCR. The overall morbidity rate was 26%, mortality rate 1.9% and case fatality rate 7.5% (Abutarbush *et al.*, 2013).

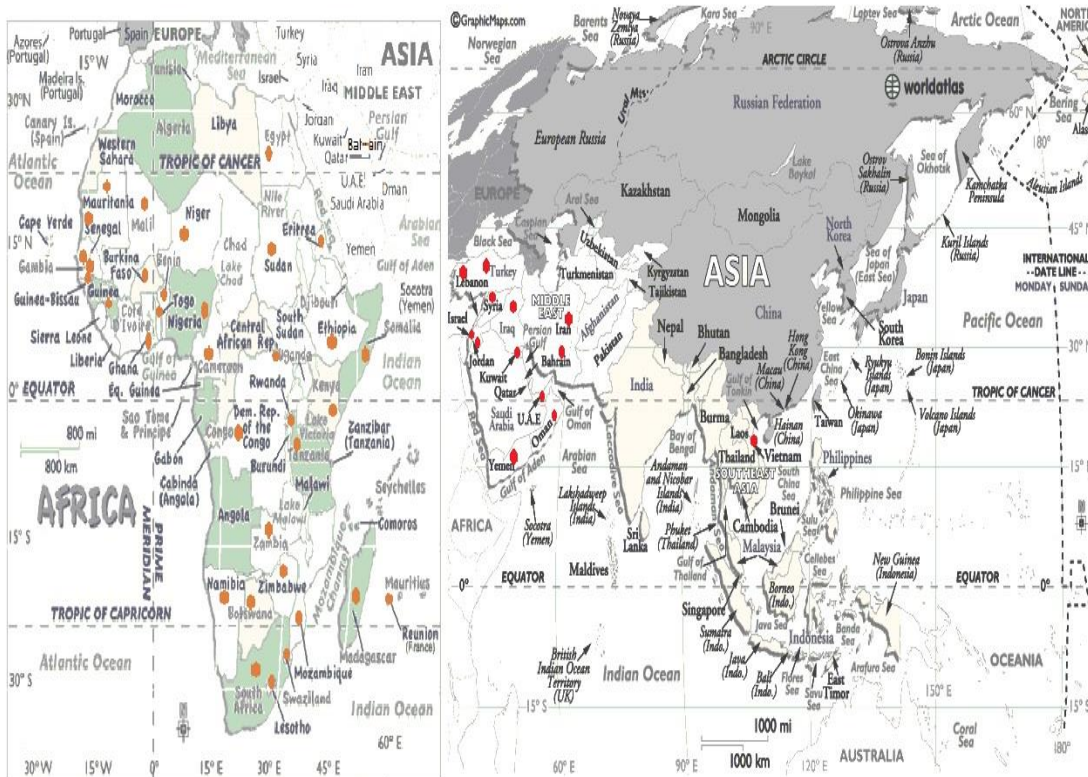
In Iran, the LSD considered as emerging disease that has been identified for the first time in 2014. In total, six cases were reported in dairy cows. The outbreaks were reported in two villages in the west of the country. The illegal movement of animals and the usual vectors are thought to be the source of the outbreak. (The cattle site, 2014).

The expectation of the travelling and invasion of the LSD to free neighbors countries are possible. LSD may invade north and west from Turkey into Europe and the Caucasus and East to Central and South Asia. In addition, Russian Federation to the north and Bulgaria and Greece to the west are considered to be at-risk countries.

## Epidemiology

### A. Morbidity and mortality rates

There is gigantic variation in the morbidity and mortality rates of LSD outbreaks. It depends on these factors: geographic location and climate; the management conditions; the nutritional status and general condition of the animal; breed of cattle affected; immune status; population levels and dissemination of putative insect vectors in the various habitats; virus virulence. The morbidity rate for LSD are ranges from 5 to 45%. However, the morbidity rates of 1 to 5 percent is considered more usual. Higher rates have been encountered in epizootics in Southern, West and East Africa and the Sudan although so far much lower rates may occur during the same epizootic. In addition, high morbidity and mortality rates 30-45 % and 12% respectively were also reported in Oman in 2009 in a farm population of Holstein cattle (Sherrylin *et al.*, 2013).



**Figure 2. Map of Lumpy skin disease distribution (The red dots show the emergence foci of the disease)**

### B. Susceptible animals

LSD has a narrow vertebrate host range. Cattle and Buffalo are the species, which become infected naturally during field outbreaks. Five occurrences of clinical cases of LSD in *Bubalus bubalis*, the Asian water buffalo have been reported (Ali *et al.*, 1990). No other domestic ruminant species becomes infected naturally during field outbreaks. All cattle breeds appear to be equally susceptible to the disease. However, some other researcher found that imported breeds with thin skins, such as *Bos taurus*, Friesland cattle and the Channel Island breeds, were far more susceptible than indigenous breeds with thicker skins, such as the Afrikaner and Afrikaner cross- breeds. Young calves are more susceptible to the disease and may develop the characteristic lesion within 24 to 48 hours, although all ages groups of animals are susceptible. A single clinical case of a *Capripox* infection, probably LSD, was described in an Arabian oryx in a zoo in Saudi Arabia. (Greth *et al.*, 1992). Experimental inoculation of some wild species such as: impala (*Aepyceros melampus*), Thomsons gazelle (*Gazella thomsonii*) and the giraffe (*Giraffa camelopardalis*), was followed by the development of LSD lesions in the skin (Young *et al.*, 1968).

### **C. Transmission**

The transmission of lumpy skin disease virus has not fully understood (Weiss, 1968; Kitching and Mellor, 1986; Carn and Kitching, 1995). The mechanical spread of the LSD virus has mainly associated with flying insects and all the possible clue confirms the field observations that epidemics of LSD occur at periods of greatest biting insect activity. Most cases are believed to be resulted from the transmission by an arthropod vector. There are variations in the attack rates from 10-15% to nearly 100% in different epidemics due to the differences in the active vector species that found in different situations. Stomoxys, the tabanids and tsetse flies, are likely to be doubtful in dry conditions and related to lower levels of transmission. However, huge mosquito-breeding sites are common in very high morbidity rates that occur after rain.

Lubinga, (2014), has been found three blood sucking hard tick species, which involved in the transmission of LSDV in sub-Saharan Africa. The three tick species identified as vectors of the disease are the *Rhipicephalus (Boophilus) decoloratus* (blue tick), *R. appendiculatus* (brown ear tick) and *Amblyomma hebraeum* (bont tick). Lubinga's study has confirmed that ticks are acted as vectors for the virus. Lubinga stated: "The ticks also act as 'reservoirs' for the virus, as it can persist in these external parasites during periods between epidemics "The virus has been found in their saliva and organs and could potentially overwinter in these ticks. Lubinga mentioned that ticks can be spread over long distances by moving along with their animal host, for instance, while feeding on migrating birds, and the change of climate due to global warming is making it possible for ticks to survive successfully and quest in areas where previously they could not survive due to very cold conditions. Same evidence has been published and reporting a possible role for hard ticks in the transmission of LSDV (Tuppurainen *et al.*, 2011). The study showed molecular evidence of transstadial and transovarial transmission of LSDV by *Rhipicephalus (Boophilus) decoloratus* ticks, and mechanical or intrastadial transmission by *Rhipicephalus appendiculatus* and *Amblyomma hebraeum* ticks. LSD virus has been isolated from *Stomoxys calcitrans* and *Musca confisicata* and transmitted experimentally using *S. calcitrans* but other vectors are also doubtful

including *Biomyia*, *Culicoides*, *Glossina* and *Musca spp.* However, in a recent study, despite the detection of virus in mosquitoes (*Anopheles stephensi*, *Culex quinquefasciatus*) the stable fly and a biting midge (*Culicoides nebeculosis*) after they had fed on cattle with lumpy skin disease, the infection did not transmit to susceptible cattle when these arthropods were allowed to re-feed on them.

Cattle can be infected by drinking water, although ingestion and direct contact transmission are not common routes, even though the virus is present in nasal and lacrimal secretions, semen, and milk of infected animals. Transmission of LSDV through semen (natural mating or artificial insemination) has not been experimentally demonstrated, but LSDV has been isolated in the semen of experimentally infected bulls.

Intra-uterine infection is assumed, which is supported by the presence of extensive skin lesions in the aborted calves (Weiss, 1968; Irons *et al.*, 2005). Some wild species (giraffe, impala, and Thomson's gazelle) have been infected by parenteral inoculation with LSD virus and have developed characteristic lesions. Lesions of LSD have not been seen on these animals, when they have been present during epizootics of the disease. Sheep and goats do not become infected during outbreaks of LSD even when held in close contact with infected cattle. African buffaloes (*Syncerus caffer*) do not show lesions in the field during epizootics of LSD, and nor did the majority of Asian water buffaloes, *Bubalus bubalis*, exposed during the Egyptian LSD epizootic. Five cases of LSD-like lesions in buffaloes were reported in Egypt. Both buffalo types may suffer an unapparent infection and seroconvert. While infection by contact can occur, this is thought to occur only at a low rate and is not considered a major component of transmission during epizootics. The movement of animals from infected herds, often months after recovery, has regularly resulted in the introduction of infection. The source of the virus is considered to be from old skin lesions. In most of Sub-Saharan Africa, the disease has been observed to appear following the seasonal rains. There is always an increase in the population of different arthropod species. Local movement of the disease in the presence of strict quarantines has been attributed to aerial movement of insect vectors in low-level air currents. The onset of frosts in South Africa and Egypt results in a great fall in the number of cases of LSD, which virtually disappears over the winter season to reappear again in the spring and summer. The disease spread throughout Egypt in the summer of 1989, despite total restrictions on animal movements. A focus of LSD appeared in Israel some 80-200 km distant from active foci of LSD transmission in Egypt, this suggests that aerial movement of biting insects had occurred. The imposition of quarantines does prevent the spread of infection by recovered animals but not by the aerial movement of vectors (Fayez and Ahmed, 2011). Direct contact is considered to be an ineffective means of transmission. Communal cattle grazing and watering points have been associated with the occurrence of LSD. Transmission of LSDV through semen (natural mating or artificial insemination) has not been experimentally demonstrated, but LSDV has been isolated in the semen of experimentally infected bulls (Weiss, 1968; Irons *et al.*, 2005).

### **Pathogenesis**

Intravenous, intradermal and subcutaneous routes are used in experimental infection. The intravenous route develops severe generalized infection, while the intraepidermal



inoculation develops only 40% to 50% of animals may developed localized lesions or no apparent disease at all. A localized swelling at the site of inoculation after four to seven days and enlargement of the regional lymph nodes, develop after subcutaneous or intradermal inoculation of cattle with LSDV (Vorster and Mapham, 2008). However, generalized eruption of skin nodules usually occurs seven to 19 days after inoculation. LSDV replicates inside the host cells such as macrophages, fibroblasts, pericytes and endothelial cell in the lymphatics and blood vessels walls lead to developing vasculitis and lymphangitis, while thrombosis and infarction may developed in severe cases. Viremia occurred after the initial febrile reaction and persisted for two weeks. In natural infection, very young calves, lactating cows, and malnourished animals seem to develop more severe disease that may be due to an impaired humoral immunity. A lifelong cell-mediated immunity is developed in most animals that recover from clinical disease. Calves are born from the infected cow acquire maternal antibodies that may protect them from clinical diseases for approximately six months. LSDV was demonstrated in saliva at least for 11 days after the development of fever, in semen for 42 days and in skin nodules for 39 days, from experimentally infected cattle.

### **Clinical signs**

The clinical signs of LSD have two febrile phases (biphasic fever), which is appeared after variant incubation period 4-12 days (usually 7 days). The temperature of the infected animals raises to 40-41.5°C, which may persist for 6-72 h or more and may rarely be up to 10 days. The infected animals also show lacrimation, increased nasal and pharyngeal secretions, anorexia, dysgalactia, general depression and a disinclination to move. The initial clinical signs of LSD are varied in severity that depends on the management system of the herd but do not relate to animal sex or age.

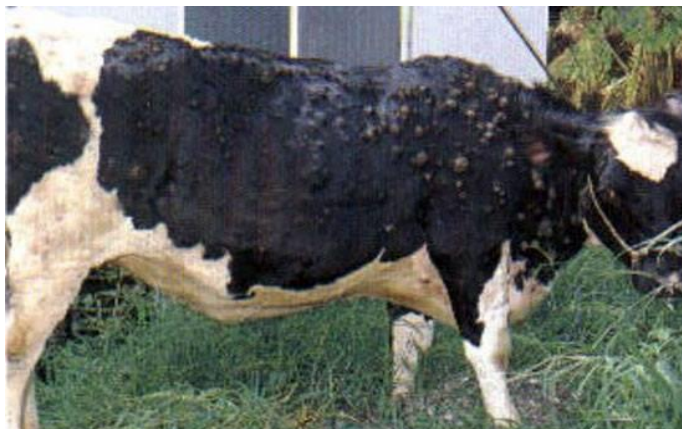Multiple firm circumscribed nodules are developed in the skin of the animals. These nodules are suddenly erupted within 1-2 days. The erupted nodules may be widespread or restricted to just a few lesions. The head, neck, the perineum, the genitalia, udder, and the limbs are the predilection sites. The whole of the skin of the infected animal is covered with lesions infrequent cases. Typical LSD lesions are round, irregular, about 5-50 mm in diameter, and appear as circumscribed areas of erect hair over a firm and slightly raised area of skin (Figure. 3). The healthy skin is clearly recognized by the adjacent skin reaction. The affected skin is hyperemic, and there may be beads of serum exuded from them. The lesions are of full skin thickness and involve epidermis, dermis and sub-cutis, often with some edema. They slowly harden and form a (dimple) indentation in the center. The regional lymph nodes are easily palpable and enlarged to 3-5 times their normal size. Some masses (lumps) may be detected in the subcutaneous tissues and are often distributed throughout the connective tissue and muscle in the body (Diesel, 1949). The disease lesions are also developed on the muzzle in the nares and the oropharynx. The muzzle shows a typical ring-like lesion due to sloughing of the necrotic lesions from the healthy surrounding epithelium. Larynx, trachea, alimentary tract particularly the abomasum may also develop lesions (necrosis and ulceration) that lead to develop severe gastro-enteritis. Keratitis is a common complication. Mucopurulent discharges appear from the nares, persistent dribbling from the mouth, coughing and often stertorous and distressed respiration, if the larynx and trachea are



involved (Ayre-Smith, 1960). After 2-3 weeks, the skin lesions gradually become harder and necrotic. Several lesions associated with the formation of hard edematous plaques, cause severe discomfort and pain and inhibit movement. Later on, the "sitfast" of LSD are developed from harder lesions (core of necrotic tissue forms a plug). There is a distinct ring of living tissue around the lesions. Some of "sitfast" may peel off, leaving a full skin thickness hole in the skin, which heals by granulation. Bacteria may invade the hole. The limbs are swelled to several times their normal size due to inflammation, oedema and large areas of necrotic lesions. Hard skin over chronically oedematous limbs may peel off, leaving large areas that can become infected or susceptible to myiasis. It was a major concern, when *Cochliomyia homnivorax* occurred in North Africa. Lesions on the teats may falling away, predisposing animals to mastitis and loss of quarters.

The common sequel of LSD is the pneumonia, associated with a large area of grey consolidation measuring 20-30 mm, which may be fatal. Inhalation of necrotic tissue from lesions higher in the respiratory tract has been approved to be fatal, many months after the initial infection. Abortion is a common sequel of the acute phase of the disease; aborted fetuses and live calves have been observed with skin lesions of LSD. Infertility is a problem following LSD infection; females remain in anoestrous for several months and most infected cow suffering from cessation of ovarian activity mainly due to poor body condition. The infected bulls, which suffer from lesions on the genitalia, may also be infertile for months.

Respiratory, mouth, pharyngeal, and ocular lesions prolong the period of anorexia and recovery. Deterioration in the general condition occurs in the severely affected animals and under range conditions the mortality can be high. The recovered animals suffered from weakness and debility for up to 6 months. The majority of affected animals develop comparatively few nodules and recover uneventfully. LSD is, however, a serious disease affecting production, although the proportion of animals developing chronic complications may be low; less than 5% of those affected (Gezahegn *et al.*, 2013).



**Figure 3.** Cow infected with LSD reveals multiple skin nodules (from Iraq recent outbreak)

### **Pathology**

## **1. Gross pathological findings**

LSD has well-described gross lesions. Skin nodules are usually uniform in size, firm round and raised, but some may fuse into large irregular and circumscribed plaques. The cut surface of the nodules is reddish-gray, in addition, to the accumulation of the reddish grey serous fluid and edema in the subcutis layer. The resolved lesions appear as indurated which is called “sitfasts” or seclude or may form deep ulcers. The typical circular necrotic alimentary lesions may also be seen on the muzzle, nasal cavity, larynx, trachea, bronchi, inside of lips, gingiva, dental pad, forestomach, abomasum, uterus, vagina, teats, udder and testes (Ali *et al.*, 1990). Regional lymph nodes are grossly enlarged and can be 3-5 times their usual size, oedematous and having pyaemic foci, in addition to local cellulitis. Muscle tissue and the fascia over limb muscle may be show nodular lesion that are grey-white surrounded by red inflammatory tissue. The same nodules are distributed throughout the carcass. It is about 10-30 mm diameter in the kidney. Interstitial or bronchopneumonia associated with 10-20 mm diameter lesions are also scattered in the lungs. These lesions result from infiltration of the large epithelioid 'celles claveleuses', described by Borrel for sheep pox. The lesions are separated from the necrotic epithelium far from the healthy tissue. The necrotic tissue sloughs away to leave an ulcer that slowly heals by granulation. Severely infected animals may show secondary bacterial pneumonia, tracheal stenosis, acute and chronic orchitis, mastitis with secondary bacterial infection, and similar lesions in the female reproductive tract (Davies *et al.*, 1971; El-Neweshy *et al.*, 2012; Kumar, 2011).

## **2. Histopathological findings**

Histopathological findings of the LSD disease are very characteristic and provide a basis for diagnosis. The lesions vary considerably depending on the stage of development. In the acute stage of the disease, it is mostly characterised by lesions of vasculitis, thrombosis, infarction, perivascular fibroplasia. Inflammatory cell are infiltrated the infected areas, which includes macrophages, lymphocytes and eosinophils. Keratinocytes, macrophages, endothelial cells and pericytes may be revealed Intracytoplasmic eosinophilic inclusions. The epidermis and dermis layers of the infected animal are showing oedema and infiltrated with large epithelioid macrophage type cells.

There are an oedema and infiltration of the epidermis and dermis with large epithelioid macrophage type cells, which have also been well described for sheep pox. They are found with plasma cells and lymphocytes in early lesions, and in older lesions, fibroblasts and polymorphonuclear leucocytes with some red cells predominate. Endothelial proliferation is seen in the blood vessels of the dermis and subcutis, with lymphocytic cuffing of the blood vessels, which lead to the thrombosis and necrosis. Specific intracytoplasmic inclusions may be found in the various epithelial elements, sebaceous glands and follicular epithelium. These are largely eosinophilic-purple and appear to have a clear halo surrounding them, which is probably a processing artefact. The lesions are substantially the same throughout the body (Burdin, 1959; Ali *et al.*, 1990; El-Neweshy *et al.*, 2012; Ali and Amina, 2013).

## **Diagnosis**

The diagnosis of LSD is based on typical clinical signs combined with laboratory confirmation of the presence of the virus or antigen (Figure. 4).

### **1. A Field presumptive diagnosis of LSD can be based upon the:**

A. Morbidity, mortality and clinical signs that reflect LSD such as:

1. Contagious disease with generalised skin nodules
2. A characteristic inverted conical necrosis of skin nodules (sitfast), Enlargement of lymph nodes draining affected areas.
3. Persistent fever, emaciation, and low mortality.
4. Pox lesions of mucous membrane of the mouth, the pharynx, epiglottis, tongue and throughout the digestive tract, mucous membranes of the nasal cavity, trachea and lungs
6. Oedema and areas of focal lobular atelectasis in lungs
7. Pleuritis with enlargement of the mediastinal lymph nodes in severe cases
8. Synovitis and tendosynovitis with fibrin in the synovial fluid
9. Pox lesions may be present in the testicles and urinary bladder

### **B. Histopathological features**

Skin biopsies of early lesions are suitable for histopathology and should be preserved in 10 percent buffered formalin. The most diagnostic histopathological features are:

1. Congestion, hemorrhage, edema, vasculitis and necrosis are always associated with nodules that are involving all skin layers, subcutaneous tissue, and often adjacent musculature.
2. Lymphoid proliferation, edema, congestion and hemorrhage.
3. Vasculitis, thrombosis, infarction, perivascular fibroplasia and cellular infiltrates
4. Intracytoplasmic eosinophilic inclusions may be seen in different cells.

### **3. A confirmative diagnosis of LSD can be based upon the:**

- **Laboratory investigations and identification of the agent based on** (OIE Terrestrial Manual, 2010; OIE, 2013):

#### **A. Isolation of the virus**

Confirmation of lumpy skin disease in a new area requires virus isolation and identification. Samples for virus isolation should be collected within the first week of the occurrence of clinical signs, before the development of neutralising antibodies (Davies, 1991; Davies *et al.*, 1971). Skin biopsies of early lesions (ones where necrosis has not occurred) provide samples that can be used for virus isolation and electron microscopy. In addition, LSD virus can be isolated from buffy coat from the blood sample collected into EDTA or heparin during the viraemic stage of LSD. Samples

should be taken from at least three animals. Samples aspirated from enlarged lymph nodes can be also used for virus isolation. LSD virus grows in tissue culture of bovine, ovine or caprine origin. Bovine dermis cells or lamb testis (LT) cells (Primary or secondary culture), are considered to be the most susceptible cells. LSD capripoxvirus have been also adapted to grow on the chorioallantoic membrane of embryonated chicken eggs and African green monkey kidney (Vero) cells, which is not recommended for primary isolation (OIE Terrestrial Manual, 2010).

## **B. Electron microscopy**

Transmission electron microscopic (TEM) diagnosis of LSD can be confirmed within a few hours of receipt of specimens. TEM demonstration of virus in negatively stained preparations of biopsy specimens taken from affected skin or mucous membranes. Mature capripox virions have an average size 320 x 260 nm and are a more oval profile and larger lateral bodies than orthopox virions (OIE Terrestrial Manual, 2010).

## **C. Fluorescent antibody tests**

Capripoxvirus antigen can also be identified on the infected cover-slips or tissue culture slides using fluorescent antibody tests.

## **D. Agar gel immunodiffusion**

An agar gel immunodiffusion (AGID) test has been used for detecting the precipitating antigen of capripoxvirus, but has the disadvantage that this antigen is shared by parapoxvirus.

## **E. Enzyme-linked immunosorbent assay**

It is made by using expressed recombinant antigen to produce P32 monospecific polyclonal antiserum and the production of monoclonal antibodies (MAbs) (Carn, *et al.*, 1994).

**F. Polymerase chain reaction (PCR)** and loop-mediated isothermal amplification (LAMP) assay have been used for detection of capripoxviruses with higher sensitivity. (Bowden *et al.*, 2009; Balinsky *et al.*, 2008).

## **• Serology**

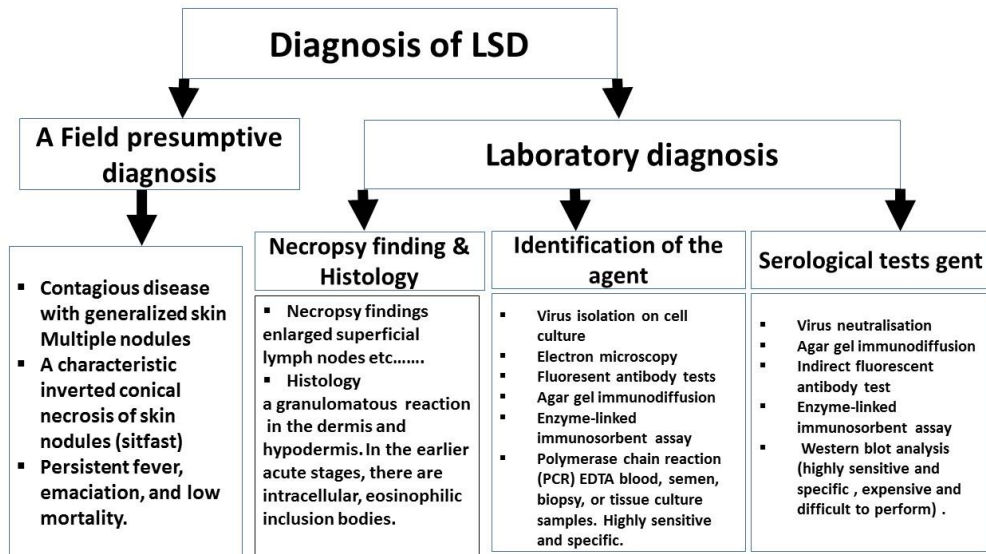
Frozen sera from both acute and convalescent animals are used. Virus neutralisation (cross reacts with all capripoxviruses) and indirect fluorescent antibody test (cross reaction with parapoxviruses) are commonly used. Enzyme-linked immunosorbent assay for the detection of antibodies against capripox virus has been developed using the expressed structural P32 protein (Carn *et al.*, 1994; Heine *et al.*, 1999). Agar gel immunodiffusion tests (This test may give false-positive reactions due to cross reaction with bovine papular stomatitis virus and pseudocowpox virus). Western blot analysis

provides a sensitive and specific system for the detection of antibody to capripoxvirus structural proteins, although the test is expensive and difficult to carry out.

### Differential diagnosis

There are many diseases causing similar signs of LSD. It is important to obtain a definite diagnosis to ensure the best preventative and control measures for susceptible herds. LSD can be confused with the following diseases:

- Pseudo-lumpy-skin disease
- Bovine virus diarrhoea/mucosal disease
- Demodicosis (Demodex)
- Bovine malignant catarrhal fever (Snotsiekte)
- Rinderpest
- Besnoitiosis
- Onchocerciasis
- Insect bite allergies



**Figure 4.** The diagnostic procedures of the LSD

### Treatment

Lumpy skin disease is caused by virus and, therefore, has no known cure. However, antibiotics, anti-inflammatory drugs or a shot of vitamins are used in some cases to treat secondary bacterial infections or to deal with fever or inflammation and improvement of the animal's appetite.

### Control

Control of Lumpy skin disease by quarantine and movement control is not very effective because biting flies and certain tick species are most probably the most important method of transmission of the disease. Although, the control of insects was not effective in preventing the spread of LSD, but use of insecticides together with repellents can be an aid in the prevention of the spread of LSD. LSD outbreaks can be eradicated by quarantines, depopulation of infected and exposed animals, proper disposal of carcasses, cleaning and disinfection of the premises and insect control.

LSD control can only be by vaccination or immunoprophylaxis. Live vaccines help control losses from lumpy skin disease in endemic areas. According to OIE, four live attenuated strains of capripoxvirus have been used as vaccines specifically for the control of LSD (Brenner *et al.*, 2006; Capstick & Coakley, 1961 & 1962; Carn *et al.*, 1994). These are: a strain of Kenyan sheep and goat pox virus passaged 18 times in lamb testis (LT) cells or fetal calf muscle cells, Yugoslavian RM 65 sheep pox strain, Romanian sheep pox strain and lumpy skin disease virus strain from South Africa, passaged 60 times in lamb kidney cells and 20 times on the chorioallantoic membrane of embryonated chicken eggs.

The following vaccines have been used in protection of the animal:

- Homologous live attenuated virus vaccine (Neethling strain: immunity conferred lasts up to 3 years).
- Heterologous live attenuated virus vaccine (Sheep or goat pox vaccine, but may cause local, sometimes severe reactions). This vaccine is not advised in countries free from sheep and goat pox because the live vaccines could otherwise provide a source of infection for the susceptible sheep and goat populations.
- There is no new generation recombinant capripox vaccines are commercially available.

## References

**Abutarbush SM, Ababneh MM, Al Zoubi IG, Al Sheyab OM, Al Zoubi MG, Alekish MO, Al Gharabat RJ. (2013).** Lumpy Skin Disease in Jordan: Disease Emergence, Clinical Signs, Complications and Preliminary-associated Economic Losses. *Transbound Emerg Dis.* Oct 21. doi: 10.1111/tbed.12177.

**Alexander RA, Plowright W and Haig DA. (1957).** Cytopathogenic agents associated with lumpy-skin disease of cattle. *Bull. Epiz. Dis. Afr.* 5:489-492.

**Ali Meawad Ahmed and Amina A. Dessouki. (2013).** Abattoir-Based Survey and Histopathological Findings of Lumpy Skin Disease in Cattle at Ismailia Abattoir. *International Journal of Bioscience, Biochemistry and Bioinformatics.* 3(4): 372-375.

**Ali BH and Obeid HM. (1977).** Investigation of the first outbreak of Lumpy skin disease in the Sudan. *Brit. Vet. J.*, 1333:184-189.

**Ali AA, Esmat M, Attia H, Selim A, Abdel-Humid YM. (1990).** Clinical and pathological studies on lumpy skin disease in Egypt. *Veterinary Record*, 127, 549–550.

**Anonymous D. (1988).** Lumpy skin disease. Vol.1.No.1, Paris: O.I.E. Disease Information.

**Ayre-Smith RA. (1960).** The symptoms and clinical diagnosis of lumpy skin disease in Egypt. *Vet. Rec.*, 127:549-550. ANONYMOUS. 1988. Lumpy skin disease. Vol. 1. No. 1, Paris:O.I.E. Disease Information .

**Ayelet G , Haftu R, Jemberie S, Belay A, Gelaye E, Sibhat B, Skjerve E and Asmare K. (2014).** Lumpy skin disease in cattle in central Ethiopia: outbreak investigation and isolation and molecular detection of lumpy skin disease virus *Rev. sci. tech. Off. int. Epiz.* 33 (3), 1-23.

**APHIS Veterinary Services Centers for Epidemiology and Animal Health. (2006).** Lumpy Skin Disease, Israel. (Impact Worksheet). <http://www.aphis.usda.gov/vs/ceah/cei/>.

**Balinsky CA, Delhon G, Smoliga G, Prarat M, French RA, Geary SJ, Rock DL, Rodriguez LL. (2008).** Rapid preclinical detection of sheeppox virus by a real-time PCR assay. *Journal of Clinical Microbiology*, 46(2):438-442. <http://jcm.asm.org/>

**Bowden TR, Coupar BE, Babiuk SL, White JR, Boyd V, Duch CJ, Shiell BJ, Ueda N, Parkyn GR, Copps JS, Boyle DB. (2009).** Detection of antibodies specific for sheeppox and goatpox viruses using recombinant capripoxvirus antigens in an indirect enzyme-linked immunosorbent assay. *Journal of Virological Methods*, 161(1):19-29. <http://www.sciencedirect.com/science/journal/01660934>

**Brenner J, Haimovitz M, Oron E, Stram Y, Fridgut O, Bumbarov V, Kuznetzova L, Oved Z, Wasserman A, Garazzi S, Perl S, Lahav D, Edery N. and Yadin H. (2006).** Lumpy skin disease (LSD) in a large dairy herd in Israel. *Isr. J. vet. Med.* 61: 73–77.

**Burdin ML. (1959).** The use of histopathological examinations of skin material for the diagnosis of lumpy skin disease in Kenya. *Bul. Epiz. Dis. Afr.*, 7:27-36

**Capstick PB, Coackley W. (1961).** Protection of cattle against lumpy skin disease. I Trials with a vaccine against Neethling type infection. *Res. Vet. Sci.*, 2:362-368.

**Capstick PB, Coakley W. (1962).** Lumpy Skin disease. The determination of the immune status of cattle by an intra-dermal test. *Res. Vet. Sci.*, 3:287-291.

**Carn VM, Kitching RP, Hammond JM, Chand P, Anderson J, Black DN. (1994).** Use of a recombinant antigen in an indirect ELISA for detecting bovine antibody to capripoxvirus. *Journal of Virological Methods*, 49(3):285-294; 30 ref.



**COETZER JAW. (2004).** Lumpy skin disease. In: Infectious Diseases of Livestock, Second Edition Coetzer J.A.W. & Justin R.C., eds. Oxford University Press, Cape Town, South Africa, 1268–1276.

**Davies FG, Krauss H, Lund LJ, Taylor M. (1971).** The laboratory diagnosis of lumpy skin disease. Res. Vet. Sci., 12:123-127.

**DAVIES FG. (1981).** Lumpy skin disease. In Virus diseases of food animals. E.P. J. Gibbs, ed. New York:Academic Press. 751-764.

**DAVIES FG. (1991) a.** Lumpy skin disease, an African capripox virus disease of cattle. Br. Vet. J., 147:489-502.

**DAVIES FG. (1991) b.** Lumpy skin disease of cattle: A growing problem in Africa and the Near East. World Animal Review, 68, 37 – 42.

**Diesel AM. (1949).** The Epizootiology of Lumpy Skin Disease in South Africa. In Proceedings of the 14th International Veterinary Congress, London, U.K., pp.492-500.

**El-Neweshy MS, El-Shemey TM and Youssef SA. (2012).** Pathologic and Immunohistochemical Findings of Natural Lumpy Skin Disease in Egyptian Cattle. Pak Vet J, xxxx, xx(x): xxx. ©2012 PVJ.

**Fayez Awadalla Salib and Ahmed Hassan Osman. (2011).** Incidence of lumpy skin disease among Egyptian cattle in Giza Governorate, Egypt. Veterinary World.4 (4):162-167.

**Gezahegn Alemayehu, Girma Zewde and Berhanu Admassu. (2013).** Risk assessments of lumpy skin diseases in Borena bull market chain and its implication for livelihoods and international trade. Trop Anim Health Prod. 45:1153–1159. DOI 10.1007/s11250-012-0340-9

**Greth A, Gourreau JM, Vassart M, Vy NB, Wyers M, Lefevre PC. (1992).** Capripoxvirus disease in an Arabian Oryx (*Oryx leucoryx*) from Saudi Arabia. Journal of Wildlife Diseases, 28(2):295-300; 15 ref.

**Heine HG, Stevens MP, Foord AJ, Boyle DB. (1999).** A capripoxvirus detection PCR and antibody ELISA based on the major antigen P32, the homolog of the vaccinia virus H3L gene. Journal of Immunological Methods, 227(1/2):187-196; 19 ref.

**House JA, Wilson TM, El Nakashly S, Karim IA, Ismail I, El Danaf N, Moussa AM, Ayoub NN. (1990).** The isolation of lumpy skin disease virus and bovine herpesvirus-4 from cattle in Egypt. Journal of Veterinary Diagnostic Investigation, 2(2):111-115; 15 ref.

**Irons PC, Tuppurainen ESM, Venter EH. (2005).** Excretion of lumpy skin disease virus in bull semen. Theriogenology, 63(5):1290-1297. Kate Aspden, Jo-Ann Passmore,

Friedrich Tiedt and Anna-Lise Williamson. (2003). Evaluation of lumpy skin disease virus, a capripoxvirus, as a replication-deficient vaccine vector. *Journal of General Virology*. 84, 1985–1996. DOI 10.1099/vir.0.19116-0.

**Kumar S M. (2011).** An Outbreak of Lumpy Skin Disease in a Holstein Dairy Herd in Oman: A Clinical Report. *Asian Journal of Animal and Veterinary Advances*, 6, 851–859.

**Kitching PR, Mellor PS (1986).** Insect transmission of Capripox viruses. *Res. Vet. Sci.*, 40:255-258.

**Lubinga J. (2014).** PhD thesis: The role of *Rhipicephalus (Boophilus) decoloratus*, *Rhipicephalus appendiculatus* and *Amblyoma hebraeum* ticks in the transmission of lumpy skin disease virus (LSDV).

**Morris JPA. (1931).** Pseudo-urticaria. Northern Rhodesia Department of Animal Health, Annual Report 1930: 12.

**OIE Terrestrial Manual. (2010).** Lumpy Skin Disease. Chapter 2.4.14. (Available at [http://www.oie.int/fileadmin/Home/eng/Health\\_standards/tahm/2](http://www.oie.int/fileadmin/Home/eng/Health_standards/tahm/2)).

**Lumpy skin disease, Iraq. (2015).**

[www.oie.int/wahis\\_2/public/wahid.php/Reviewreport/Review?reportid=14444&newlang=en](http://www.oie.int/wahis_2/public/wahid.php/Reviewreport/Review?reportid=14444&newlang=en)

**Sherrylin Wainwright, Ahmed El Idrissi, Raffaele Mattioli, Markos Tibbo, Felix Njeumi, Eran Raizman. (2013).** Emergence of lumpy skin disease in the Eastern Mediterranean Basin countries. *empres watch*. Volume 29 NOVEMBER 2013. © FAO 2013. <http://www.fao.org/ag/empres.html>

**Shimshony A. (1989).** In: Proc. 93rd Ann. Mtg. US Animal Health Assoc., 334-335.

**Shimshony A, Economides P. (2006).** Disease prevention and preparedness for animal health emergencies in the Middle East. *Revue Scientifique et Technique - Office International des Épizooties*, 25(1):253-269.

**The cattle site, Lumpy Skin Disease Reported in Iran. (2014).** <http://www.thecattlesite.com/news/47156/lumpy-skin-disease-reported-in-iran#sthash.TSIfuN3U.dpuf>

**Thomas A D and Mare C V E (1945).** Knopvelsiekte. *J. S. Afr. Vet. Med. Assoc.*, 16: 36-43.

**Tageldin Mohamed Hassan & Wallace David Brian & Gerdes Gertruida Hermanna & Putterill John Fraser & Greyling Roelf Rudolph & Phosiwa Maanda Noaxe & Al Busaidy Rashied Mohammed & Al Ismaaily Sultan Issa. (2014).** Lumpy

skin disease of cattle: an emerging problem in the Sultanate of Oman. *Trop Anim Health Prod* (2014) 46:241–246. DOI 10.1007/s11250-013-0483-3.

**Tuppurainen ESM and Oura CAL. (2012).** Review: lumpy skin disease: an emerging threat to Europe, the Middle East and Asia. *Transbound. emerg. Dis.* 59: 40–48.

**Tulman E, Afonso C, Lu Z, Zsak L, Kutish G & Rock D. (2001).** Genome of LSDV. *J Virol* 75, 7122–7130.

**Tulman E R, Afonso C, Lu Z & 7 other authors. (2002).** The genomes of sheeppox and goatpox viruses. *J Virol* 76, 6054–6061.

**Vorster J H and Mapham P H. (2008).** Lumpy skin disease. *Livestock Health and Production Review.* Jaargang 10/ 1: 16-21.

**Von Backstrom U (1945).** Ngamiland cattle disease. Preliminary report on a new disease, the aetiological agent probably being of an infectious nature. *J. S. Afr. Vet. Med. Assoc.*, 16: 29-35.

**World Organisation for Animal Health (OIE). (2013).** Lumpy skin disease. *Terrestrial Animal Health Code.* OIE, Paris.

**Woods JA. (1988).** Lumpy skin disease—A Review. *Tropical Animal Health and Production.* 20: 11–17.

**Young E, Basson PA, Weiss K, (1968).** Experimental infection of the giraffe, impala and the Cape buffalo with lumpy skin disease virus. *Onderstepoort J. Vet. Res.*, 37:79-86.

**Weiss KE, (1968).** Lumpy skin disease. In: *Virology Monographs, Vol. 3.* Vienna, Austria; New York, USA: Springer-Verlag, 111-131.