



## The effect of camel hump fat oil on skin wounds healing in rabbits

Hussein Ahmed Ibraheem<sup>1</sup>; Mustafa Abd AL-kareem Abd AL-zahraa; <sup>1</sup>Ali  
Abbas Ajeel<sup>2\*</sup> 

<https://orcid.org/0000-0001-8154-7291>

<sup>1</sup> College of Veterinary Medicine, AL Muthanna University/ AL Muthanna, Samawah, Iraq.

<sup>2</sup> Department of surgery / College of Veterinary Medicine, AL Muthanna University/ AL Muthanna, Samawah, Iraq.

### ARTICLE INFO

**Received:** 09.10.2021

**Revised:** 09.11. 2021

**Accepted:** 13.11.2021

**Publish online:** 14.11.2021

**\*Corresponding author:**

**Professor Ali Abbas Ajeel:**

Email address:

[draliabbas1972@mu.edu.iq](mailto:draliabbas1972@mu.edu.iq)

### Abstract

*This study aimed to assess the efficiency of the camel hump fat oil from a one-humped camel (*Camelus dromedarius*) on surgical skin wound healing in the rabbit. The research was*

carried out on 6 rabbits, both male and female. Four circles of full-thickness skin wounds were made on the back of each animal under general anesthesia with a mixture of ketamine HCL 5% ( 35 mg/kg BW ) and xylazine HCL 2% ( 5 mg/kg BW ). Rabbits were divided into two equal groups (control and treated groups). The Control group let for healing without any treatment, while the treated group was treated with camel hump fat oil once daily for three days. Macroscopic parameters (percentage of wound contraction and healing time) were used to evaluate the efficacy of the camel hump fat oil on skin wound healing 7,14,21 days after surgery. The result showed a progressive reduction in the wound surface area with time, and a higher mean percentage of wound contraction was obtained in wounds treated with the camel hump fat oil. Also, the results showed that camel hump fat oil accelerated wound healing activity compared to the control group. Wound contraction was significantly higher (  $75.55 \pm 3.84$ ,  $100.00 \pm 0.00$  in 2nd and 3rd weeks respectively ), and the healing time was faster (  $21.00 \pm 0.00$  ) in the treated group than in control one (  $26.00 \pm 1.00$  ). The study concludes that camel hump fat oil promotes significantly ( $p < 0.05$ ) wound contraction and reduces the epithelization period in the rabbit model.

**To Cite this article:** Hussein Ahmed Ibraheem ; Mustafa Abd AL-kareem Abd AL-zahraa; Ali Abbas Ajeel (2021). The effect of camel hump fat oil on skin wounds healing in rabbits. (2021). MRVSA. 10 (2): 45-52. [Doi: http://dx.doi.org/10.22428/mrvsa-2021-00102-03](http://dx.doi.org/10.22428/mrvsa-2021-00102-03)

**Keywords:** Camel hump, Fat, Healing, Rabbit, Wound.

### Introduction

Wound healing is a complex process of the replacement of dead tissue by living one. It runs in three basic phases, inflammatory, proliferative, and maturation phase



(Toporcer *et al.*, 2006). All these steps are orchestrated in a controlled manner by a variety of cytokines, including growth factors (Umachigi *et al.*, 2007) such as epidermal growth factor (EGF), fibroblast growth factor (FGF), and transforming growth factor-beta (TGF $\beta$ ) (Ali Kokuludağ, 1999; Kwon *et al.*, 2006; Tanaka *et al.*, 2005).

Camels are multipurpose animals; they are used for milk, meat, and hide supply, as well as for other purposes such as transport, entertainment, and competition, as in racing. The camel is of significant socio-economic importance in many arid and semi-arid parts of the world, and its milk constitutes an important component of human diets in these regions (Farah, 1986). Camel milk is still the most important nutritional source for pastoralists in many African and Asian countries. Camels produce more milk of high nutritional quality and for a longer period than other species in an environment that may be rightly termed as hostile in terms of extreme temperature, drought, and lack of pasture (Valérie, 2007).

Many studies have examined the composition of camel hump fat using thin-layer chromatography. The main fatty acid composition of camel hump fat is palmitic acid, stearic acid, oleic acid, myristic acid. Camel hump fat contains more saturated fatty acids (74%) than unsaturated fatty acids. This partially accounts for the fact that camel hump fat has a higher melting point than, for example, porcine fat (Rawdah *et al.*, 1994; Haasmann, 1998; Kadim *et al.*, 2013).

*Camelus* 'Camelid' is represented by two domesticated species: the one-humped camel (*Camelus dromedarius*) and the two-humped, shorter-legged (*Camelus bactrianus*) camel. While the one-humped camel is found in the hot arid areas of the Middle East, Africa, and Eastern Asia, the two-humped camel is found in Central Asia (Jassim and Naji 2001; Kadim *et al.*, 2013). The domesticated one-humped camel, *C. dromedarius*, is one of the most abundant, representing 90% of the genus *Camelus* in the Arabian Desert (Kadim *et al.*, 2013; Ataya *et al.*, 2012). They have great tolerance to harsh conditions of high temperatures, solar ultraviolet (UV) radiation, water scarcity, and poor vegetation (Jassim and Naji, 2001).

The camel has unique anatomy; it's the only animal having humps on the torso mainly made up of fat. The fat in a camel is not stored subcutaneously over an extensive area of the animal, as with humans and other animals that store their fat mixed in with muscle tissue or in a layer beneath the skin. In a healthy, well-fed dromedary camel, the hump weight can exceed 40 kg, representing (5-13%) of the carcass weight. Camel fat is also present in small proportions in the milk, blood, meat, and bones. Hump and other fat deposits contain mixtures of fatty acids, and most of these are esterified as triglycerides or phospholipids and vary according to their anatomical location in the body (Kadim *et al.*, 2013).

*Camelus dromedarius* (or one-humped camels) endure harsh conditions, including extreme temperatures and high solar ultraviolet (UV) radiation in desert wilderness areas. This remarkable survival in the harsh desert conditions is attributed to distinctive bodily features enabling them to cope with this toxic environment (Jassim *et al.*, 2018).



The camel hump is considered offal from camel; nevertheless, in some African camel-producing countries it is considered an important ingredient and commonly used for cooking. Hump fat has been used as a traditional medicine to ease hemorrhoid pains, and the hump fat has also been used to remove tapeworm. Other products from the camel, including meat, milk, cheese, and even urine and dung, are considered medicinal in the Middle East and North Africa. For instance, camel milk was reported to cure jaundice, tuberculosis, and asthma and camel dung infusion in water is used to cure earaches and to remove eye cataracts in some parts of Nigeria (Kadim *et al.*, 2013).

The unique features of the camel genome and proteome not only enable them to survive and thrive under harsh environmental conditions but also make them less susceptible to various pathological conditions. Camels employ several intrinsic immunological and molecular mechanisms against pathogenic agents and pathological conditions (Fazil and Hofmann, 1981).

The highest percentage of unsaturated fatty acids and lowest percentage of saturated fatty acids are found in camels of less than one year. In contrast, the opposite trend applies to animals in the 1-3-year-old age group. The hump cholesterol is (139 mg/100 g fresh weight), which is lower than those found in the lamb and beef adipose tissues (196 and 206 mg/100g fresh weight), respectively (Kadim *et al.*, 2013).

In the surgical and medical fields alike, we currently stand at the dawn of an exciting new era in therapeutics. This study investigates the activity of the oil rendered from the hump fat on skin wound healing in rabbits model.

## **Materials & Methods**

Six healthy adult local rabbits weighing between 1.50-2 kg were used for the study. Animals were kept in individual standard cages. Food and water were provided ad libitum.

### **Camel Hump Oil Extraction**

One kg of fresh hump fats was obtained from an adult male dromedary camel immediately after slaughtering. Camel hump fat was minced to facilitate its melted. Fats were placed in an oven with a lab beaker and heated to 60°C for 30 min. The crude melted fat was cleaned from fibers using a food strainer. The clear liquid fat was then collected in a clean, sterile container and stored in a fridge at 10°C to hold for use.

### **Animal treatment**

Animals were surgically prepared in each group then anesthetized with a mixture of ketamine HCL 5% ( 35 mg/kg BW ) and xylazine HCL 2% ( 5 mg/kg BW ) ( Lipman *et al.*, 1990). Four circles of full-thickness skin wounds (15mm diameter) were made on the back of each animal ( Figure- 1 ). Prepared hump oil applied immediately after surgery on the full wound ( Figure- 2 )once daily for three days.

### **Evaluation parameters**



Macroscopic parameters were used to evaluate the efficacy of the camel hump fat oil on skin wound healing on 7,14,21 days after surgery in two groups ( Figures- 3 to 8 ). The wound size was calculated through the percentage of wound contraction by using the following equation: Percentage of wound contraction= [(Initial wound size-specific day wound size) / Initial wound size] × 100 (Srivastava and Durgaprasad, 2008).

### **Statistical analysis**

The results obtained were statistically analyzed using a t-test. All values were expressed as Mean ± Standard deviation. The level of significance was set at  $p < 0.05$ .

### **Results & Discussion**

Morphological parameters were used to evaluate the efficacy of the camel hump fat oil on skin wound healing in rabbits. The results showed a progressive reduction in the wound surface area with time in two groups (Figures 3 to 8 ), and the best results were in (Figures 7 and 8 ) of the treated group compared to the control one. The epithelization period was significantly shortened ( $p < 0.05$ ) in the dromedary hump fat oil group ( $21 \pm 0.00$  days) compared to the control group ( $26 \pm 1.00$  days), meaning the healing was faster in the treated group ( Table- 2 ). The results of different percentages of wound contraction in (Table-1) showed the higher mean percentage of wound contraction was in wounds treated with the camel hump fat oil ( $100.00 \pm 0.00$ ) compared to the control group ( $77.77 \pm 3.85$ ). Oil derived from dromedary hump fat is white with a soft creamy texture that quickly absorbs the skin. Oil derived from fat-tailed sheep has a whitish color with a soft creamy texture that absorbs less on the skin than camelid fat cream. Oil derived from cow fat is yellowish with a soft creamy texture that absorbs much less on the skin than of camelid fat cream.

The major components in the camel hump fat, including saturated fatty acids and noticeable values of omega 3, 6, 9, and Vitamin E, have contributed to shield/protect/prevent skin damage and may also have unique anti-tumor properties with novel dual radiation protection and mitigation/healing properties, camel hump fats may also serve as anti-inflammatory and healing agents to help the animal to cope with the workload and the harsh desert conditions (Jassim et al., 2018).

The hump oil does not clog the pores of the skin. It is not irritating to the skin and can be used in various compositions, including ointments, creams, and cosmetics. It can be combined with many active ingredients, which are beneficial or otherwise therapeutic. In any event, hump oil in any such application serves similar functions of increasing skin penetrability, moisturizing, antioxidant, anti-inflammatory, and healing without adverse effects (Nafiseh Nili, 2016).

Jassim et al. (2016) described compounds, compositions, and methods for the treatment of skin conditions with oil derived from camel hump fat, and their results suggest that when human skin is treated with camelid fat cream, the blood flow improves within 30 seconds. The increased flow lasts more than 6 hours. The increased blood flow enriches the tissues with all-important growth factors for cells and tissues, qualities tied to skin



aging, reducing wrinkles, lighter skin pigmentation, relieving dry skin, and leaving the treatment site naturally healthy-looking.

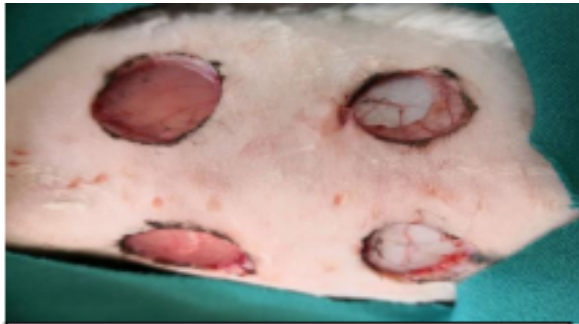
**Table (1): Percentage of wound contraction in two groups**

Groups	Percentage of wound contraction \ Time		
	1 <sup>st</sup> week	2 <sup>nd</sup> week	3 <sup>rd</sup> week
Control	22.22 ±3.84	51.10 ±3.85	77.77 ±3.85
Treated	26.60 ±6.66	75.55 ±3.84	100.00±0.00

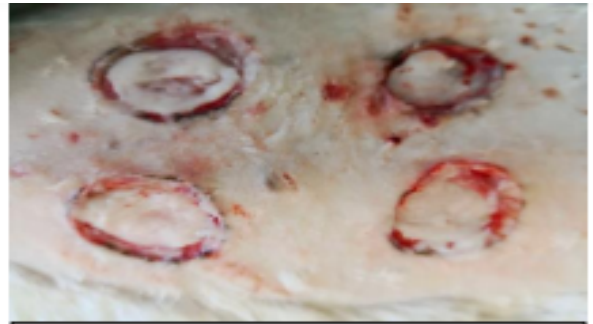**Table (2): Epithelization period (days) in two groups.**

Groups	Epithelization period /days
Control	26.00 ±1.00
Treated	21.00 ±0.00

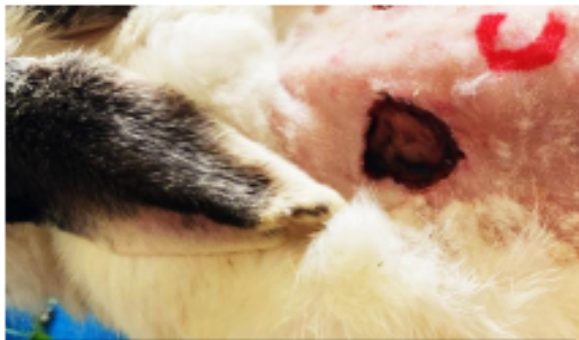




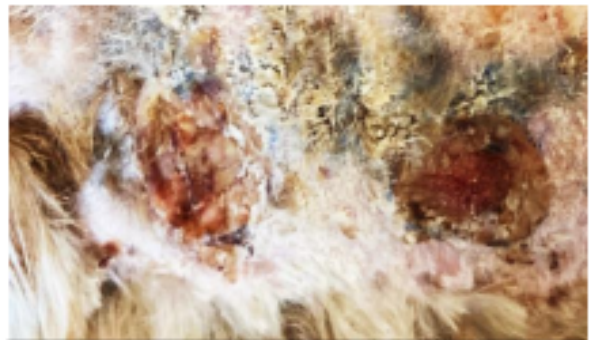
(Figure:1) Control group first day



(Figure:2) Treated group first day



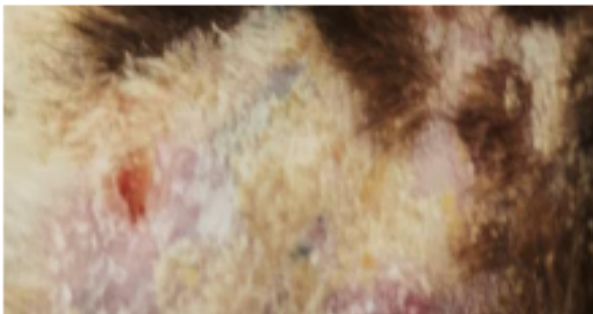(Figure:3) Control 1 week



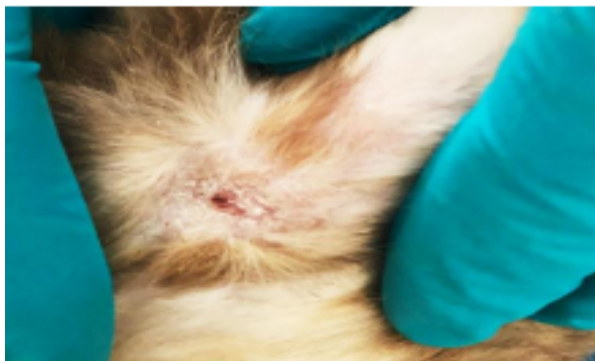
(Figure:4) Treated 1 week



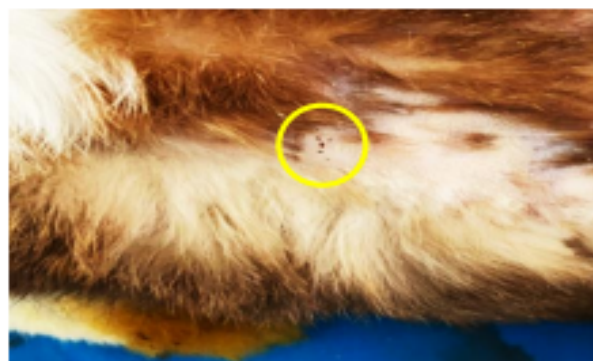(Figure:5) Control 2 weeks



(Figure:6) Treated 2 weeks



(Figure:7) Control 21 days



(Figure:8) Treated 21 days

## Conclusions

The study conclude that camel hump fat oil promotes significantly wound contraction and reduces epithelization period in rabbit model.

## References

1. **Ali Kokuludağ MD. (1999).** Growth factors. *Turk J Immunol.* 4: S 52-53.
2. **Ataya FS, Fouad D, Malik A, Saeed HM. (2012).** Molecular cloning and 3D structure modeling of APEX1, DNA base excision repair enzyme from the camel, *Camelus dromedaries.* *Int J Mol Sci.* 13(7): 8578–96. <https://www.ncbi.nlm.nih.gov/pmc/articles/PMC3430252/>
3. **Farah Z. (1986).** Effect of heat treatment on whey proteins of camel milk. *Milchwissenschaft.* 41:763–765. <https://agris.fao.org/agris-search/search.do?recordID=DE19870036110>
4. **Fazil M, and Hofmann R. (1981).** Haltung und Krankheiten des Kamels. *Tieraerztl. Prax.* 9, 389–402.
5. **Haasmann SO. (1998).** Analytical characterization of camel meat and milk fat. A thesis submitted for the degree of Doctor of Philosophy. University of Brunei: Department of Chemistry. <https://bura.brunel.ac.uk/handle/2438/6961>
6. **Jassim SA, Naji MA. (2001).** The desert ship: heritage and science. *Biologist (UK).* 48(6):268-72. <https://pubmed.ncbi.nlm.nih.gov/11740078/>
7. **Jassim SA, Aldoori AA., AbdulMounam MA, Faraj BR, AbdulHameed FF, Limoges RG (2018).** Photoprotection Comprising Oil Derived from Dromedary Camel Hump Fat. *Annual Research & Review in Biology* 27(3). Article no.ARRB.42132. <https://www.journalarrb.com/index.php/ARRB/article/view/25565>
8. **Jassim S, Aldoori A, AbdulMounam M, Faraj B, AbdulHameed F, & Limoges R G. (2018).** Photoprotection Comprising Oil Derived from Dromedary Camel Hump Fat. *Annual Research & Review in Biology*, 27(3), 1-11. <https://doi.org/10.9734/ARRB/2018/42132>
9. **Kadim IT, Mahgoub O, Faye B, Farouk MM (2013).** Camel meat and meat products. Oxford: CABI. <https://agris.fao.org/agris-search/search.do?recordID=FR2013100448>
10. **Kwon YB, Kim HW, Roh DH, Yoon SY, Baek RM, Kim JY, Kweon HY, Lee KG, Park YH. and Lee JH. (2006).** Topical application of epidermal growth factor accelerates wound healing by myofibroblast proliferation and collagen



- synthesis in rat. J. Vet. Sci. 7(2), 105-109.  
<https://pubmed.ncbi.nlm.nih.gov/16645332/>
11. **Nafiseh Nili. (2016).** Camel humipol - based herbal compositions and method of making the same. Patent Application Publication, 2014.US 2014/0178487 A1.
  12. **Lipman N S, Marini R P, Erdman S E. (1990).** A comparison of ketamine/xylazine and ketamine/xylazine/acepromazine anesthesia in the rabbit. Lab Anim Sci. 40(4):395-8. <https://pubmed.ncbi.nlm.nih.gov/2166867/>
  13. **Rawdah T N, Zamil El-Faer M, Koreish S A. (1994).** Fatty acid composition of the meat and fat of the one-humped camel (*camelus dromedarius*) Published by Elsevier Ltd. DOI: 10.1016/0309-1740(94)90151-1. <https://pubmed.ncbi.nlm.nih.gov/22059419/>
  14. **Srivastava P, Durgaprasad S. (2008).** Burn wound healing property of Cocos nucifera : An appraisal. Indian J Pharmacol. 40(4):144-146. <https://www.ncbi.nlm.nih.gov/pmc/articles/PMC2792613/>
  15. **Sabah A A. Jassim, Atheer A. Aldoori, Moutaz A. AbdulMounam, Basil R. Faraj, Farqad F. AbdulHameed and Richard G. Limoges. (2018).** Photoprotection Comprising Oil Derived from Dromedary Camel Hump Fat. Annual Research & Review in Biology 27(3): 1-11. <https://www.ncbi.nlm.nih.gov/pmc/articles/PMC2792613/>
  16. **Tanaka A, Nagate T. and Matsuda, H. (2005).** Acceleration of wound healing by gelatin film dressing with epidermal growth factor. J. Vet. Med. Sci. 67 (9): 909-913. <https://pubmed.ncbi.nlm.nih.gov/16210803/>
  17. **Toporcer T, Grendel T, Vidinský B, Gal P, Sabo J. and Hudák R. (2006).** Mechanical properties of skin wounds after Atropa belladonna application in rats. J. Metals Materials. 16(1): 25-29. <http://jmmm.material.chula.ac.th/index.php/jmmm/article/view/248>
  18. **Valérie E. (2007).** Hygienic status of camel milk in Dubai (United Arab Emirates) under two different milking management systems. Thesis for the attainment of the title of Doctor in Veterinary Medicine from the Veterinary Faculty Ludwig-Maximilians-Universität München, Munich. 1–120. [https://edoc.ub.uni-muenchen.de/7663/1/Eberlein\\_Valerie.pdf](https://edoc.ub.uni-muenchen.de/7663/1/Eberlein_Valerie.pdf)
  19. **Umachigi SP, Jayaveera KN, Ashok Kumar CK and Kumar GS. (2007).** Antimicrobial, wound healing and antioxidant potential of Couroupita guianensis in rats. Pharmacology online. 3: 269-281. <https://pubmed.ncbi.nlm.nih.gov/20161916/>

