



Bloodless Liver Resection using modified Electrocautery in the Goats

Abdulbari A. Al faris*¹; Jinan A. Bannai¹; Rana K. Abdulsamd¹

¹ Department of Surgery and Theriogeniology, College of Veterinary Medicine, University of Basra, Iraq

ARTICLE INFO

Received: 07.01.2015

Revised: 22. 01.2015

Accepted: 25.01.2015

Publish online: 29. 01.2015

*Corresponding author:

Email address:

vetedu2000@yahoo.com

Abstract

This study was designed to assess the feasibility and safety of partial hepatectomy by using thermal energy to resect and control bleeding. In addition, to investigate the effect of conventional surgery on the liver function test in the goat. Eight adult goats were used in this study. The goats were divided randomly into

two groups. Partial hepatectomy was done by modified electrocautery in the first group, while simple interrupted mattress sutures were used in the second group. Hematological parameters were estimated for both experimental groups. The biochemical autoanalyzer were used to determine: alanine aminotransferase (ALT), aspartate transferase (AST) and alkaline phosphatase (ALP). The hematological parameters (PCV, Hb% and total leukocytic count) were estimated at zero, 1st, 2nd, and 3rd day of surgical operation. Gross necropsy and histopathological findings of the liver were also reported. The results showed that partial hepatectomy could perform successfully in goats by using modified electrocautery. At Post-surgical operation by electrocautery, the goats showed acceptable hematological and enzymes parameters, in addition, to the normal appetite and absence of complication and death due to hepatic resection. Necropsy findings showed normal healing of the operating site and an absence of adhesion and normal liver's color. There were no significant differences in the means values of the liver functions tests (ALP, AST and ALT). Moreover, there were no significance variations in hematological parameters (PCV, Hb% and WBC Count). In conclusion, this study showed that the application of modified electrocautery technique in partial hepatectomy revealed more feasible and safe method for the liver regeneration, proliferation of bile duct, decrease and absence of hematological side effect.

To cite this article: Abdulbari A. Al faris; Jinan A. Bannai and Rana K. Abdulsamd, (2015). Bloodless Liver Resection using modified Electrocautery in the Goats. MRVSA. 4 (1), 1-10. DOI: [10.22428/mrvsa.2307-8073.2015.00411.x](https://doi.org/10.22428/mrvsa.2307-8073.2015.00411.x)

Keywords: Liver, resection, electrocautery, Goats, University of Basra.

Introduction

The liver is a large system responsible for metabolism, detoxification, and body secretory functions. Hence, it regulates various important metabolic functions in

mammalian systems. Hepatic damage is associated with the distortion of these metabolic functions (Khan and Mudan, 2007). Liver resection, in which a part of the liver that contains a single area of cancer, or a noncancerous tumor or cyst is removed (Zhang and Xia, 2008). Consequently, lesions such as hemangiomas, adenomas, complex cysts, or fibronodular hyperplasia are often excised by enucleation or anatomic resections with limitation (Melendez *et al.*, 1998). The knowledge of liver anatomy and advances in imaging technology have made segmental anatomic liver resections easier by reducing intraoperative bleeding and by providing adequate margins and a low rate of postoperative complications (Billingsley *et al.*, 1998). There are always risks with any surgery, however, in the hepatectomy removing 25-60% of the liver carries more than the average risk, pain, bleeding, infection and or injury to other areas of the abdomen. In addition, death is a potential danger of hepatectomy (Joshi *et al.*, 2002). The liver has ability to re-grow itself again after remove or lost part of its structures. Up to 80 percent can be safely removed, as long as the rest is healthy. The piece of liver that is left behind grows back until the liver reaches its original size (Anonymous, 2009). Liver enzyme activity induction may be associated with changes in hepatic weight, histological evidence of abnormal hepatocytes, alteration of blood serum clinical biochemistry analyses and pleiotropic gene expression in the veterinary medicine (Najdat *et al.*, 2014). The aim of this study was to investigate the liver resection by electrocautery in goat.

Material and methods

Eight healthy adult goat of both sexes weight of 25 -30 kg (average 28.5 kg) were used in this study and divided randomly into 2 groups. The animals were housed in animal farm, College of Veterinary Medicine, University of Basra. This research was approved by research committee / College of Veterinary Medicine / Basra University.

Animal Preparation

The goats were fasted for 12 hours before the procedure. They were pre-medicated with Xylazine at a dose of 0.1 mg / kg (B.W) and Ketamine at a dose of 11mg /kg (B.W) (Ismail, 2010). Antibiotics (Penicillin –Streptomycin 10 mg/kg B.W) were given preoperatively and postoperatively for 7 consecutive days. Blood samples were collected from experimental animals at zero, 1, 2 and 3 day from the jugular vein. .

Measurement of liver enzyme test and hematological parameters

Blood samples were used for biochemical test and hematological parameters. Biochemical autoanalyzer were used to determine: alanine aminotransferase (ALT), aspartate transferase (AST) and alkaline phosphatase (ALP). The hematological parameters (PCV, Hb% and total leukocytic count) were estimated at zero, 1st, 2nd, and 3rd day of surgical operation.

Operative Technique

The parallel region to the last rib was prepared for surgical operation from the right flank by clipping, shaving of the hair and finally disinfected with Tincture Iodine. Later on, this animal was shifted to the surgical room after preoperative care and anesthesia. Surgical incision (about 10 cm parallel to the last rib within the mid-third of the left abdominal side of the animal), was made that also included the skin of the abdominal wall and peritoneum. Dissecting forceps used to explore the liver and remove any previous adhesions if found. Then, partial hepatectomy was done after the fixation and preparation procedures. In Group A, the part of the liver was removed by monopolar electrocautery. The electrocautery was applied for 5-7 seconds until the part separation was achieved and no bleeding occurred at the resected site (Figure. 1). In group B, the part of the liver was removed by two rows of simple interrupted mattress sutures. The surgical Cutgut No 3.0 was applied. Then, continuous suture was used to merge the edge using cutguts No.2. Later on the clamp removed and the area was examined to ensure the absence of bleeding. Lastly, continuous suturing was used for the abdominal muscles using catgut, and the skin was sutured with blanket suture using silk No.3 (Figure.2, A-k).



Figure 1. Modified electrocautery

Results

The partial hepatectomy was performed successfully in all experimental goats. The animals didn't revealed any signs of complication or death due to hepatic resection. Postoperatively, the experimental animals were in a good general health condition and revealed normal clinical evaluation. The goats also showed limitation in activity at the first three days and this might be due to pain or large surgical incision. The necropsy finding in group A, showed no signs of adhesion of resection area with other adjacent structure and the liver revealed clear and shiny color (Figure. 3). In group B, animals were showed mild adhesion between omentum and the site of the operation. The physical examination (rectal temperature, respiratory rate, and heart rate) of the animals, which was recorded at the pre-operation and post-operation (daily for 3 days after the operation), revealed variation between the experimental groups. The respiratory rate and temperature revealed significant difference in conventional group at the 3rd day after surgery.

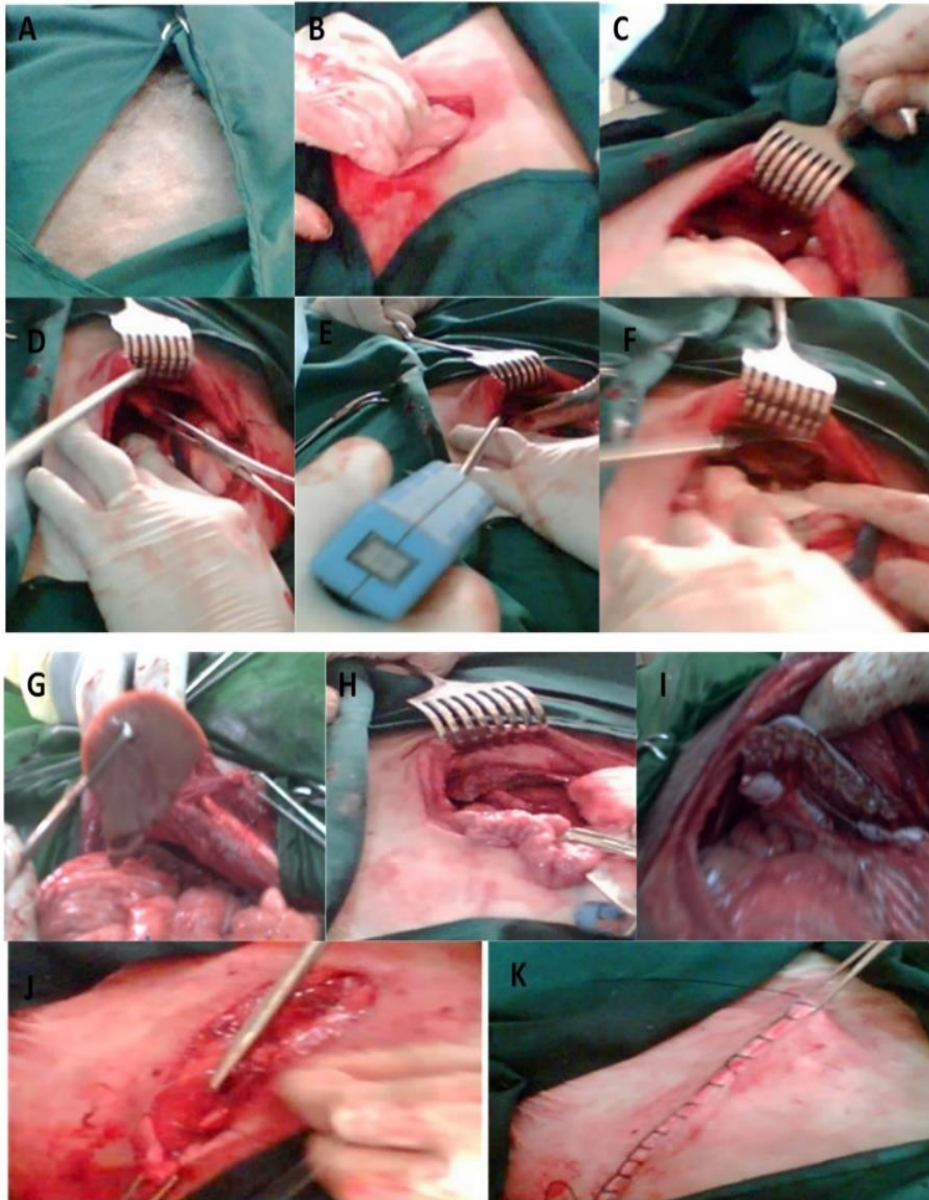


Figure 2. Shows the surgical procedure: **(A)** Preparation of the area of the operation, **(B, C)** the surgeon reached the abdominal cavity. Observing the liver, **(D)** Fixing the liver, **(E,F)** Cutting a piece of the liver, **(G)** Getting the cut piece out the abdomen, **(H)** The liver after cutting a piece of it by modified electrocautery group(A), **(I)** The liver after cutting a piece of liver show the edge of the cut part was sutured by two rows of simple interrupted mattress in group B. **(J)** abdominal muscles sutured with continuous suture, **(K)** the skin was sutured with blanket suture.

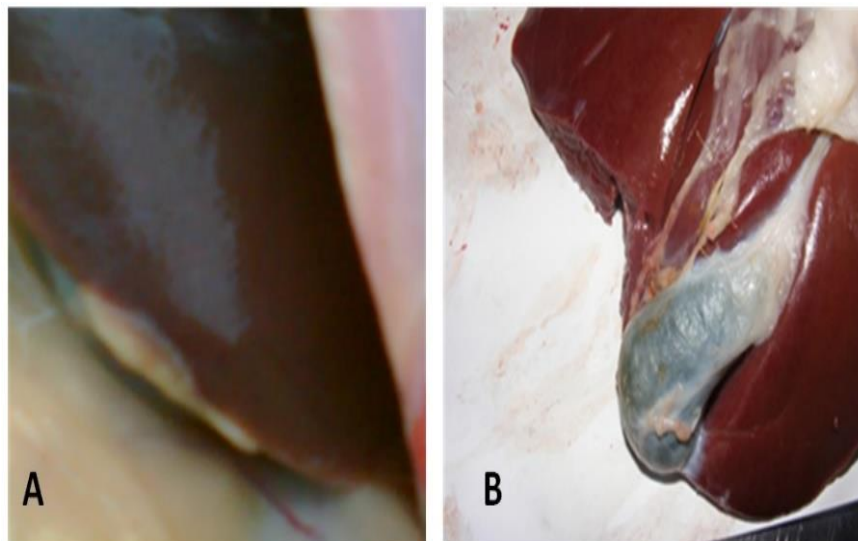


Figure 3. The liver in group (A); showed no adhesion with any surrounding organs A, and Show the liver is very clear, and the color is shine B.

The effect of partial hepatectomy on haematological parameters (PCV) in the period (1st, 2nd and 3rd days) revealed significant decrease ($P < 0.01$) between the two groups (Table 1).

Table 1. The effect of partial hepatectomy on P.C.V in the goats (Mean \pm S.D)

Time	Zero Day	1 st Day	2 nd Day	3 rd Day
Group				
(A)	33.000 \pm 2.945	35.250 \pm 2.874	35.750 \pm 2.502	31.750 \pm 2.755
(B)	32.250 \pm 2.219	34.000 \pm 2.163	35.500 \pm 2.083	33.500 \pm 3.108

The results of total WBC estimation at the 1st, 2nd and 3days post-operation in the partial hepatectomy (group A) revealed significant increase (table. 2).

Table 2. The effect of partial hepatectomy on WBC in the goats (Mean \pm S.D)

Time	Zero Day	1 st Day	2 nd Day	3 rd Day
Group				
(A)	5400.00 \pm 1290.99	8240.00 \pm 1190.238	12374.00 \pm 946.484	13749.00 \pm 500.00
(B)	7123.000 \pm 273.664	9000.00 \pm 1630.993	10123.00 \pm 1545.847	10874.00 \pm 1249.00

The hemoglobin concentration revealed no statistical differences ($P > 0.05$) between experimental group at zero day when compared to first three days postoperatively (Table. 3). The effects of partial hepatectomy on Liver Enzymes (AST, ALP, ALT) showed significant increase ($P > 0.05$) in the AST between group A and B (Table. 4).

However, the concentration of ALT showed no significant increase ($P>0.05$) between group A and B postoperatively, but in the 3rd day the ALT decreased significantly in group B (Table. 5). The concentration of plasma ALP revealed a significant decrease ($P<0.05$) in group A in compared to group B (Table. 6).

Table 3. The effect of partial hepatectomy on Hb% in the goats (Mean \pm S.D.)

Time Group	Zero Day	1 st Day	2 nd Day	3 rd Day
(A)	11.12 \pm 0.719	11.762 \pm 0.512	11.887 \pm 0.262	9.637 \pm 1.612
(B)	9.652 \pm 1.262	10.750 \pm 0.878	10.750 \pm 0.878	9.570 \pm 0.292

Table 4. The effect of partial hepatectomy on AST in the goats (Mean \pm S.D.)

Time Group	Zero Day	1 st Day	2 nd Day	3 rd Day
(A)	1.202 \pm 0.691	230.675 \pm 91.072	369.567 \pm 67.834	397.127 \pm 166.186
(B)	7.067 \pm 5.940	295.690 \pm 13.700	400.627 \pm 12.240	287.240 \pm 104.806

Table 5. The effect of partial hepatectomy on ALT in the goats (Mean \pm S.D.)

Time Group	Zero Day	1 st Day	2 nd Day	3 rd Day
(A)	16.697 \pm 1.703	3.102 \pm 3.238	24.422 \pm 1.800	27.560 \pm 12.108
(B)	16.955 \pm 1.153	2.977 \pm 3.097	23.710 \pm 1.988	15.820 \pm 1.655

Table 6. The effect of partial hepatectomy on A.L.P. in the goats (Mean \pm S.D)

Time Group	Zero Day	1 st Day	2 nd Day	3 rd Day
(A)	47.537 \pm 0.682	34.500 \pm 2.691	2.465 \pm 5.330	8.375 \pm 2.637
(B)	47.737 \pm 0.582	6.375 \pm 10.223	4.250 \pm 3.493	12.225 \pm 1.767

The histopathological investigation of the liver samples, revealed congestion of the central vein and periportal area, dilatation of the portal vein in group A. Furthermore, the accumulation of the edematous fluid. The liver sections in group B revealed hemorrhagic area, degeneration and infiltration of the inflammatory cell. In addition, formation of fibrin network, proliferation of bile ducts and hepatocyte proliferation were also seen (Figure 4.A-H).

Discussion

The rate of postoperative complications such as adhesion were lower, in the electrocautery hepatectomy group, which may be due to reduce the bleeding during the operation. Normal appetites but limitation in the activities in first three days postoperatively were observed that might happened due to pain or the large surgical incision. These observations are compatible with others (Agha and Muir, 2003; Al-Khilani, 2010). In this study, the electrocautery technique employed by the heat. This heat produced by the electrode and acted to coagulate the liver tissue throw cutting procedure that permitted hepatectomy with reduced blood loss. This opinion is in agreement with previous work (Tsalis *et al.*, 2007).

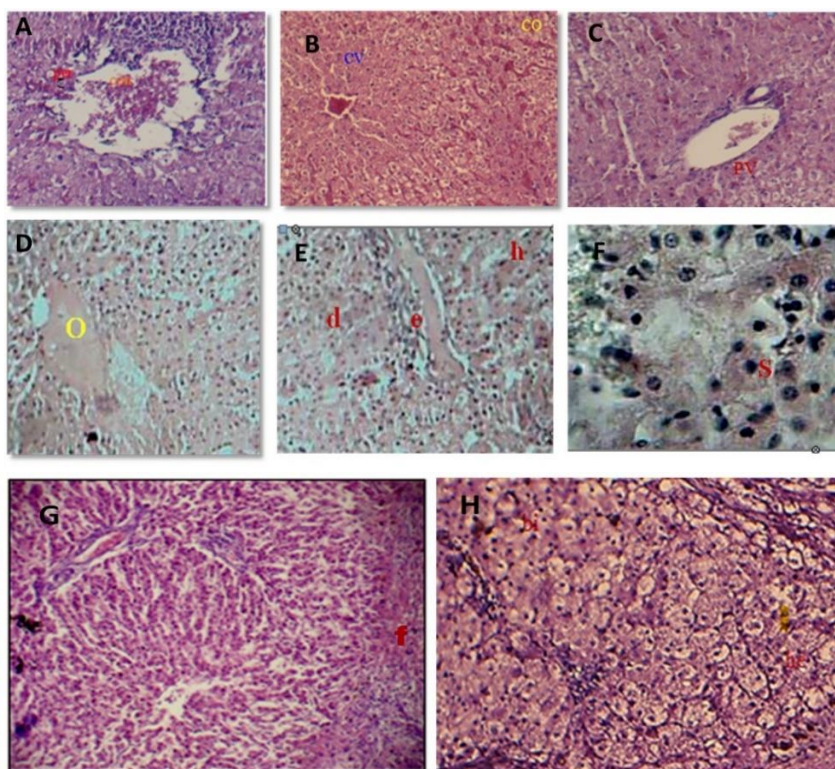


Figure 4. Shows histopathological changes of liver sections taken from experimental goat: [A]section of liver tissue from goat in group A showing the congested central vein(cv), dilated congestion portal vein (co) ; [B] section of liver tissue from goat in group A showing periportal (per) and congestion portal veins(con) ; [C] section of liver tissue from goat in group A showing dilated the portal veins (PV) ; [D]section of liver tissue from goat in group A show edematous fluid (o) ; [E] section of liver tissue from goat in group B show hemorrhage area (h) degeneration (d) in inflammatory cell (e) ; [F]section of liver tissue from goat in group B show swelling of hepatocytes(s); [G] section of liver tissue from goat in group B show present of network of fibrin(f) ; [H] section of liver tissue from goat in group B show proliferation bile ducts (bi),circumscribed area of hypertrophy and proliferated hepatocyte (he).

The physical parameters including rectal temperature, respiratory rate, and heart rate revealed no significant differences after surgery this was also recorded previously by others (Verma *et al.*, 2006; Al-Badrany, 2006; Al-Khilani, 2010).

Blood samples were collected pre and post-surgery, and revealed increasing in the white blood cells at post operation samples and decreased in the PCV. This results are in compatible with other (Masahiro *et al.*, 2009).

The Liver Enzymes showed an increase in AST, ALT values in both experimental groups, this result accords with (Bannai, 2011; Al-Khilani, 2010), which may be referred to damages of muscles due to surgical incisions. However, there were no significant variations in the level of ALP. Moreover, the increase in the level of AST indicated that the source of AST was not the liver (Hamel, 2003). Following some incentives, such as toxic insult, infection, or partial hepatectomy, the liver rapidly restores its ideal mass to maintain normal purpose (Lens *et al.*, 2014).

The Necropsy findings of group A revealed the full restoration. The effective of electrocautery was coagulating the blood vessels and liver tissues at the site of operation, this finding is in agreement with previous reports (Al-Hasan and Al-Heani, 2009).

The histopathological findings in electrocautery partial hepatectomy group revealed many changes at the site of operation. These included a lesser amount of edematous fluid with dilated congested central vein that might occurred due to active electrocautery procedure. This device was acted to cut and coagulate blood vessels at the same time on the site of operation. These observations are in agreement with previous research (Al-Hasan and Al-Heani, 2009). In group B, the histopathological changes were hemorrhage area, degeneration and infiltration of inflammatory cell. These changes might be due to bleeding from the liver or injury occurred manually during the surgical incision and cutting of the liver, this is in agreement with (Bannai, 2011) who did partial hepatectomy in goats. In conclusion, this study approved that the advantages of modified electrocautery technique in partial hepatectomy in comparison with the conventional technique.

Reference

Agha R and Muir G. (2003). Does laprascopic surgery spell the end of the open surgeon. *J. Res. Soci. Med*, 196: 544-546.

Al-Badrany MS. (2006). Cholecystectomy and liver biopsy achievement by laparoscopy in dog. PhD. Thesis. College of Veterinary Medicine / University of Mosul.

Al-Hasan AM and Al-Heani WA. (2009). Laparoscopic Partial Splenectomy in Dogs. *J. of Animal and Veterinary Advances*, 8 (11): 2232-2240.

Al-Khilani MA. (2010). A comparative study of complete and partial laproscopic cholecystectomy in goat. PhD. Thesis, College of Veterinary Medicine / University of Baghdad – Iraq.

Anonymous. (2009). Liver resection. Patient information fact. Memorial Sloan-Kettering Cancer Center 1275 York Avenue New York. <http://www.mskcc.org/search/site/Liver%20resection>.

Bannai JA.(2011). Partial hepatectomy by laproscopic and convetional surgery Acomparative study. MSc. Thesis, College of Veterinary Medicine / University of Basra/Iraq.

Billingsley KG, Jarnagin WR, Fong Y, Blumgart LH. (1998). Segment-oriented hepatic resection in the management of malignant neoplasms of the liver. J Am Coll Surg, 187:471–81.

Hamel (2003). Clinical chemistry. In: Tighe, M.M and Brown M. (eds:) Mosby;s Comprehensive Review for veterinary technicians. 2nd ed. Chapter, Mosby, 6. 98-99.

Ismail ZB.(2010). Effect of Xylazine – Ketamine – Diazepam anesthesia on certain clinical and arterial blood gas parameters in sheep and goats. Comp. Clin. Pathol, 19:11-14.

Khan Z Aamir and Mudan S. Satvinder (2007) Liver regeneration: mechanisms, mysteries and more. ANZ J Surg 77: 9-14.

Joshi M Rajeev, Wagle PK, Darbari A, Chhabaa DG, Patnaik PS and Katrak MP. (2002). Hepatic resection for benign liver pathology. Report of two cases. Indian J. of Gastroenterology, 21:157-159.

Masahiro M, Satomi S, Yuri K, Takashi K, Takahiro K, Daisuke K, Yoshito N and Takumi O. (2009). Phenobarbital (PB)-induced changes in blood coagulation related parameters in pregnant rats, lactating rats and pups. The Journal of Toxicological Sciences, 34(6):603-10. DOI: 10.2131/jts.34.603

Melendez JA, Arslan V, Fischer ME, Wuest D, Jarnagin WR, Fong Y, Blumgart LH. (1998) Perioperative outcomes of major hepatic resections under low central venous pressure anesthesia: blood loss, blood transfusion, and the risk of postoperative renal dysfunction. J Am Coll Surg, 187(6):620-5.

Najdat Ali AL-Kadhi, Kasim Sakran Abass, Kamal Ali Salih, Mohammed Kalil Turab. (2014). Effect of storage methods on viability of some hepatic enzymes in farm animals. Advances in Life Science and Technology, 18:1-6.

Lens, S., Leoz, M., Nazal, L., Bruguera, M., & Parés, A. (2014). Bezafibrate normalizes alkaline phosphatase in primary biliary cirrhosis patients with incomplete response to ursodeoxycholic acid. Liver International, 34(2):197-203.

Tsalis K, Blouhos K, Vasiliadis K, Kalfadis S, Tsachalis T, Sawas I and Betsis D. (2007). Bloodless laparoscopic liver resection using radiofrequency thermal energy in the porcine model surg. Laparosc. Endosc. percutan Tech. 17 (1):22-25

Verma GR, Lyngdoh TS, Kaman L, Bala I. (2006). Placement of 0.5% bupivacaine-soaked Surgicel in the gallbladder bed is effective for pain after laparoscopic cholecystectomy. *Surgical Endoscopy and Other Interventional Techniques*.20 (10):1560-1564.

Zhang YY and Xia HH. (2008). Novel therapeutic approaches for hepatocellular carcinoma: fact and fiction. *World J. Gastroenterol*, 14:1641- 1642.-203.