



Clinical, Immunological, and Epidemiological Studies of Nasopharyngeal Myiasis in Camels slaughtered in Al-Muthanna Province

Tareq Jaffer faal Al-jindeel ¹, Hussein Jabar Jasim ¹, Nawar Jasim Alsalih ¹, Ali Mosa Rashid Al-Yasari ¹
¹College of Veterinary Medicine/ Al-Muthanna University, Iraq. University

ARTICLE INFO

Received: 22.02.2018
Revised: 28.02.2018
Accepted: 08.03.2018
Publish online: 25.06.2018

***Corresponding author:**
 Hussein Jabar Jasim
 Email address:
husseinjaseem2014@gmail.com

Introduction

The aim of this study was to investigate the clinical signs related to infected camels by *C. titillator* larvae and to determine prevalence and incidence of *C. titillator* larvae in the camels. This

study was conducted on 864 camels slaughtered at Al Muthanna abattoir during the period extended from 1st September 2015 to 30th August 2016. Fever, emaciation, loss of appetite, congestion of mucous membrane, enlargement of lymph nodes, nasal discharge, neurological signs, increase respiratory rate, frequent sneezing and snoring during breathing were the most common clinical signs of *C. titillator* infection. The numbers of infested camels by *C. titillator* larvae were 352 (40.07%) out of 864. There was a relationship between the climatic conditions and the incidence of *C. titillator* larvae with the highest (89.02%) and lowest (6.15%) percentages in January and July respectively. Additionally, the highest (70.1%) and the lowest (29.8%) infestation percentages were recorded in 4-7 years, and 8 months to 2 years old camels respectively. According to sex, infestation percentages were (56.6%) and (37.36%) for female and male respectively. This study also showed variations in the mean concentrations of total protein (g/l), albumin, β -, γ -globulins between the infected and healthy camels. In conclusion, this study approved incidence of *C. titillator* infection in camelids with variation in the incidence that depends on the climate and age and sex of the animals. We recommend to do more studies in other provinces in Iraq to determine the epidemiological map of these parasites in camelids.

To cite this article: Tareq Jaffer faal Al-jindeel, Hussein Jabar Jasim, Nawar Jasim Alsalih, Ali Mosa Rashid Al-Yasari. (2018). Clinical, Immunological, and Epidemiological Studies of Nasopharyngeal Myiasis in Camels slaughtered in Al-Muthanna Province. MRVSA. 7 (2), 51-61.

doi: <http://dx.doi.org/10.22428/mrvsa-2018-00727>

Keywords: Camels, Nasopharyngeal Myiasis, Clinical, Epidemiology.

Introduction

Recently, the number of studies on camelid families in terms of science and research has greatly increased. Camel is physiologically and anatomically adapted to survive

harsh conditions and play an important role in human's life how lived in desert and semi-desert and even in irrigate land. Camels like other domestics animals are also exposed to various pathogenic, infectious agents and disease (Borji *et al.*, 2010). The herd growth and productivity of camels are restricted by various infectious agents such as parasites, which lead to mortality and high morbidity (Bekele, 2010). There are different types of ectoparasites that can affect the health of camels such as; sarcoptic mange, tick, and fly infestations (Oryan *et al.*, 2008). Nasopharyngeal myiasis is one of the most important problems of camels due to their responsibility for significant economic losses due to the presence of the larvae of *Cephalopina titillator*, which is a common obligate parasite of the Oestridea family that attacks only camels (Abd El-Rahman, 2010). In Iraq, camels were firstly infested with myiasis in 1977 (Abdul-Hab and Al-Affass, 1977). The adult fly is widely distributed in areas where camels are found (Hussein *et al.*, 1982; Higgins, 1985). During part of its life cycle, the female fly darts towards the nostrils and deposits its larvae directly into the nasal cavity. The larval stages are sometimes known as 'al-naghaf' in Arabic, loosely translatable as 'nose worm'. The larvae crawl up to the nasopharyngeal and sometimes reach the paranasal sinuses and molt twice while attached to the nasopharyngeal and paranasal mucous membranes and remain attached to the mucous membrane of these organs for up to 11 months. During this time, they feed and cause extensive irritation and tissue damage (Bekele, 2001; Shakerian *et al.*, 2011). Nasopharyngeal myiasis of camels causes severe economic losses such as; reduction of milk production, destroy host tissues and decrease body weight, fertility. Furthermore, myiasis has the ability to reduce host physiological functions, show difficulty in breathing, sneeze, extensive irritation, and tissue damage that has been reported in infested camels (Otranto, 2001; Razi Jalali *et al.*, 2016). The severity of clinical signs depends on the damage caused by migrating larvae (Otranto, 2001). In acute cases, the infected camels may die from meningitis caused by secondary bacterial or viral infections (Musa *et al.*, 1989). In addition, (Morsy *et al.*, 1998) mentioned that the mechanical damages such as penetrating the ethmoid bone by the larvae may assist in the introduction of bacteria and viruses to the cerebrospinal canal. Although considerable numbers of camels are reared in semi-arid areas of Iraq and they have important role in livelihood of people, very few studies have been done on clinical and epidemiological aspects of parasitic infestations, especially myiasis as a serious threat for camel health. The aim of this study was to determine the prevalence rate and the influence of seasonal variation, age and gender on the prevalence of the infestation. Moreover, the clinical signs associated with *C. titillator* larvae infection in camels are also described. The results of this study may provide a rationale starting point for treatment planning and controlling measurements against the fly and the larvae and may even shed the light on some aspects of the life cycle pattern and ecology of the parasite.

Materials and methods

Study Area and Animals

This study was carried out randomly on 864 camels slaughtered from the slaughterhouse of Alkider, Rumathia and Samawah in Muthanna province, south of

Iraq during the period from September 2015 to August 2016. The number of camels slaughtered varied from 4 to 6 a day. The slaughterhouse was visited three days a week. The examined camels were arranged into three age groups; 8 months-2 years old, 2-4 years old and 4-7 years old. Samples were collected from slaughtered camels with different sexes about 546 male and 318 female. Their age was determined on the basis of dental formula. Furthermore, general clinical examination was performed on all camels in the slaughterhouse and includes general condition examination (hump structure), body temperature and external shape such as the nature of the camels' lint and weaknesses, respiratory rate, heart rate and examination of superficial lymph node. The signs of Myiasis were observed and recorded.

Samples Collection and Diagnosis


After slaughtering, the heads of the slaughtered infested camels were separated from the rest of the body. The head was split longitudinally to expose the different regions of nasal cavity, nasopharyngeal area, frontal sinuses and turbinate bones. Then, careful gross examination was performed to detect the presence of the first, second and third instars of *Cephalopina titillater* larvae and the possible gross abnormalities accompanied with the presence of the larval infestation. The gross damage to the site of attachment was described and recorded. The recovered larvae from each camel were carefully collected, washed in physiological saline solution (NaCl 0.9%) and preserved in a separate container for each carcass with 70% alcohol. All samples were labeled (characteristics include sex and age of the animal and history) and transferred to parasitology laboratory of College of Veterinary Medicine/Al-Muthanna University. Subsequently, diagnosis of *Cephalopina titillater* larvae was done according to specification of posterior spiracles as described by (Zumpt, 1965). This study was conducted on 30 samples collected from infected and control camels with age range 8 month-7 years, 10 samples from males 10 from females and 10 of apparently healthy camels. Blood samples (5 ml) for the analyses were collected from the jugular vein by vacutainer tubes without anticoagulant. To evaluate total serum protein concentration and protein fractions, the blood serum was separated by centrifugation at 2,500 rpm for 10 min, Serum protein fractions were separated using electrophoresis on cellulose acetate plate in barbital buffer, pH 8.6, at 180 V, 4 mA, for 15 min according to manufacturer's instructions (Helena Biosciences, UK). After separation, the protein bands were stained with Ponceau S for 10 min, then destained with 5% acetic acid for 2 min and dehydrated in methanol for 2 min, and cleared with clearing solution (30% glacial acetic acid, 70% absolute methanol, and 4% clear aid) for 10 min, Finally, after drying at 50-60°C for 15 min, the relative levels of separated proteins were scanned using a densitometer at 525 nm. Protein fractions were identified and quantified by a computer software (Zamani Ahmadm Mahmudi *et al.*, 2012). Albumin to globulin (A/G) ratio was then calculated from the electrophoretic scan. Data were analyzed using SAS software package (ver 9.1.3). The normal distribution of the data was evaluated using Kolmogorov and Smirnov test. A two-sample t-test was used to compare the means between groups, and a $P \leq 0.05$ was considered to be significant.

Results

The total numbers of clinically examined camels are 864 of various age and sex. Clinical examinations of camels subjected to the study were showed a varied clinical signs as revealed in table (1) In this table, the most clinical signs were observed in infected camels include frequent sneezing, snoring during breathing and congestion of mucous membranes in 38.7%, 36.6 % and 35.9 % respectively. While the less common signs were observed in infected camels are the enlargement of lymph node, increase heart rate and neurological signs (head shaking and trying to rubbing the nose of other animals or walls) in 1.8%, 9.2% and 14% respectively. Additionally, the current study revealed the three phases of larvae of *C. titillator* of camels infested (Fig.1). The larval phase of *C. titillator* is mainly passed in the third stage. The first larvae stage (L1) is only about 2-4mm in length and up to 15 mm in the second stage. While, the mature white or grey third-stage larvae grow up to 15-23 mm (Figure-1). The gross examination of carcass of *C. titillator* infested camels after slaughtering was restricted to the nasal cavity, nasopharyngeal area, frontal sinuses and turbinate bones. The present study revealed that the most larvae were found and attached to the mucosa of the Nasopharynx, while a rare were found in the nasal cavity. Larvae were also observed in the frontal sinuses and turbinate bones. The nasal cavities of *C. titillator* infested camel were congested and obstructed by thick, dark-colored mucus, sever inflammation and degeneration changes., Some larvae remain active and moving nearly freely, but others larvae were attached firmly to the pharyngeal mucosa by their hooks and when removed, firm reddish nodules marked the sites of attachment. Whereas, the mucous membrane of nasopharyngeal region of infested camels by myiasis was congested, swollen, hemorrhagic, edematous with abundant mucous secretion. Furthermore, many nodules were observed in other parts of the nasopharyngeal area and these nodules were hard in consistency and contained calcareous material at sites of larvae attachment. The damage of *C. titillator* infested camel greatly depends on the number of migratory larvae. (Figures 2 and 3). The results of epidemiological study revealed that only 352 out of 864 examined camels were infected by *C. titillator* larvae during the study period from September 2015 to August 2016 at infestation rate of (40.07%). As is revealed in (Table-2), the percentage of infestation with *C. titillator* larvae was associated with specific seasons. The examination showed highest percentage of infestation with *C. titillator* larvae which occurs in January 89.02%, followed by February 68.35%. Whilst, the lower percentage of infestation with *C. titillator* larvae occurs in July 6.15% followed by June 9.45 with significant differences ($P < 0.01$) (Figure-4). Table-3) showed the prevalence rates and differences among the different age groups and sexes. In this table, the highest percentage of infestation with *C. titillator* larvae was recorded in females in 56.6%. Whereas, the lower percentage of infestation with *C. titillator* larvae were recorded in male (37.36%). and showed significant differences ($P < 0.01$) (Figure-5). Furthermore, this table showed the highest percentage of infestation with *C. titillator* larvae that occurs in age group between 4 to 7 years in 65.61 %, followed by age group between 2 to 4 years in 35.58%. While , the present study showed that lower percentage of infestation were recorded in camels with age group between 8 months to 2 years old in 22.95% ($P < 0.0001$).

Table 1: Shows Important Clinical Signs Related to Infected Camels by *C. titillator* larvae.

Percentage of infection %	Numbers of animals	Clinical sings
33.5	290	Emaciation
18.28	158	Fever
25.46	220	Loss of appetite
35.9	311	Congestion of mucous membranes
35.3	305	Nasal discharge (Sticky)
23.14	200	Increase Respiratory rate
9.2	80	Increase heart rate
1.8	16	Enlargement of lymph node
14	121	Neurological signs (shaking of the head)
38.7	335	Frequent sneezing
36.6	317	Snoring during breathing



Fig(1).Shows the three phases of larvae of *C. titillator* from camels infested (L1,L2 and L3).

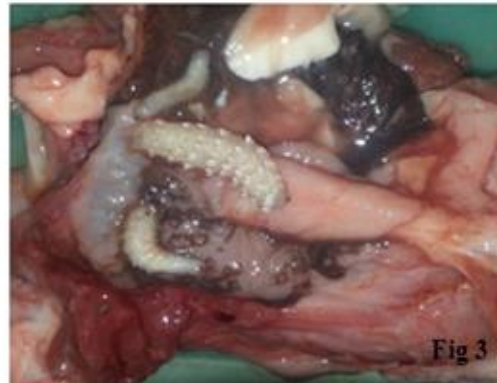
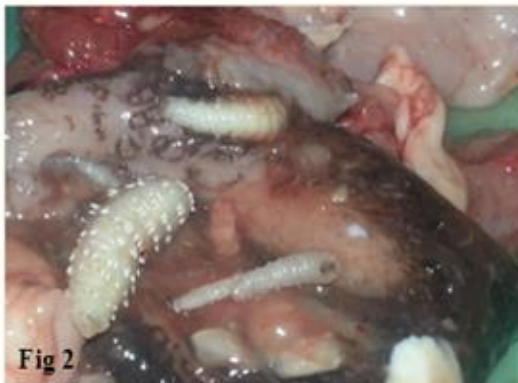
Fig (2,3).The nasopharyngeal region of infested camel by *C. titillator* larvae showing Congested (dark color) , Hemorrhagic , Swollen and Edematous mucosa

Table (2): Shows the percentages of infested camels by *C. titillator* larvae according to months of years.

Months of year	No. of camels examined	No of infested camels	Percentage of infestation %
September	66	21	31.81
October	70	29	41.42
November	78	40	51.28
December 2015	74	47	63.51
January 2016	82	73	89.02
February	79	54	68.35
March	72	41	56.94
April	65	16	24.61
May	70	11	15.71
June	74	7	9.45
July	65	4	6.15
August	69	9	13.04
Total	864	352	40.07

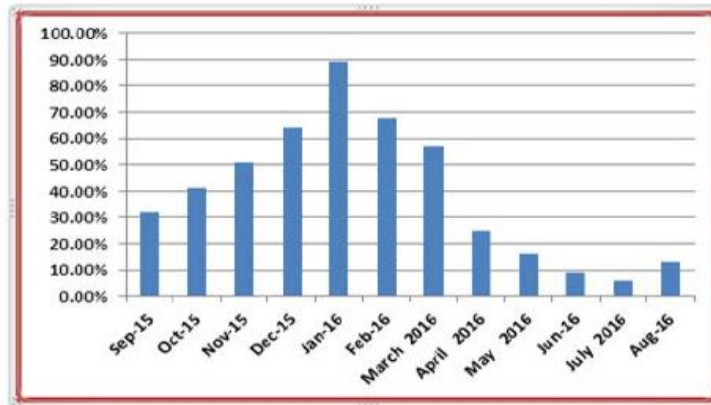


Figure 4: Show the percentage of infested camels by *C. titillator* larvae according to months of years.

Table 3: Shows the percentage of infested camels by *C. titillator* larvae based on age (year) and sex.

Age				Male			Female		
	Inspected	Infected	Percentage %	Inspected	Infected	Percentage %	Inspected	Infected	Percentage %
8 monthes-2 years	244	56	22.95	140	25	17.8	104	31	29.8
2-4 years	399	142	35.58	282	93	32.9	117	49	41.8
4-7 years	221	154	69.68	124	86	69.35	97	68	70.1
Total	864	352	40.74	546	204	37.36	318	148	46.54

Table 4: Show serum protein electrophoresis concentration measured to Infected Camels by *C. titillator* larvae.

Index	Band	Ref. Area %	Conc. g/L Lmean ± SD	Range g/L
1	Albumin	25.55%	25.00 ±2.40	35.00-50.00
2	Alpha 1	7.56%	7.33 ±0.14	1.00-4.00
3	Alpha2	10.12%	9.69 ±0.30	6.00-12.00
4	Beta	31.25%	29.92 ±0.80	6.00-12.00
5	Gamma	25.12%	24.05 ±0.53	7.00-15.55
Total			96.00	
Ratio		0.28		

Table 5: Show serum protein electrophoresis concentration measured to healthy Camels by *C. titillator* larvae.

Index	Band	Ref. Area %	Conc. g/L Lmean ± SD	Range g/L
1	Albumin	45.55 %	40.00 ±0.22	35.00-50.00
2	Alpha 1	3.56%	4.33±0.30	1.00-4.00
3	Alpha2	8.12%	7.69 ±0.30	6.00-12.00
4	Beta	10.25%	22.6 ±0.20	6.00-12.00
5	Gamma	12.12%	13.55 ±0.20	7.00-15.55
Total			87.97	
Ratio		0.28		

Nasopharyngeal myiasis, *Cephalopina titillator* larvae is one of the most non-ignorable problems of the livestock industry in many camel-producing areas of the world due to their responsibilities for significant economic loss to the camel industry. The results of the present study revealed that the local camels were infected with *C. titillator* larvae and this fact confirms that the Myiasis is widespread in areas where camels are found in Iraq. There are few studies that have described the clinical signs in camels infested by *C. titillator* larvae. The present study revealed that *C. titillator* larvae infected camels showed similar clinical signs and came in line with (Hussein *et al.*, 1982, Atiyah *et al.*, 2011). Moreover, the results showed that the camels infected by *C. titillator* larvae clinically showed fever, emaciation, appetite loss, congestion of mucous membrane, enlargement of lymph nodes, nasal discharge, neurological signs, difficulty in breathing, frequent sneezing and snoring during breathing, all these signs were agreed with those reported (Zumpt, 1965; Otranto, 2001). The increase in body temperature occurs due to the stimulation of thermoregulatory center in the hypothalamus or result from hyperthermia, this stimulation occurs because of the release of endogenous pyrogens due to cellular lysis during the infestation (Zumpt, 1965). Furthermore, infestation with *C. titillator* larvae led to lose their appetite, could be attributed to present fever (Zumpt, 1965;

Radstitis, 2000). Also, In heavy infection, the breathing in the camels Infested by *C. titillator* larvae is greatly impaired, frequent sneeze and snort during breathing was explained as a result to blockage of the nasopharynx by larvae and/ or mucofibrinous secretions (Zumpt, 1965; Hussein *et al.*, 1982).The congestion of mucous membranes was showed on conjunctivae and 3rd eye lid during the examination refer to hemostasis disturbances which may occur due to the thrombocytopenia and the disturbance of other clotting factors the as a result of increasing in the clotting time (Smith,1996). While, the other clinical signs such as; neurological signs and irritations may occur due to the larvae may reach the cranial cavity causing meningitis or some of the larvae penetrating the ethmoid bone may assist in the Introduction of bacteria and viruses to the cerebrospinal canal (Hussein *et al.*, 1982). The overall rate of infestation among 864 examined camel heads was 40.7%.These results were agreed with (AbulHab, *et al.*, 1977; Atiyah *et al.*, 2011). This study showed that the highest percentage of infection with *C. titillator* larvae was occurred in winter (January and February) with prevalence of infection 89.02%% and 68.35 % respectively. Whereas, lower percentage of infection with *C. titillator* larvae that were occurs in summer, July followed by with prevalence of infection 6.15 % and 9.45 %respectively. These results were consistent with several previous studies which show that climate plays an important role in the prevalence of *C. titillator* larvae in the camels in different places of Iraq by Atiyah *et al.*, (2011) in Al-Qadissiya province 42.43% and Abul-Hab and Al-Affass, (1977) in central Iraq was 46.7%. Also agreement with studies in other parts of the world conducted by Alahmed, (2002) in Saudi Arabia41%; Ramadan, (1997) in Egypt 37%; Al- Ani and Zuhair, (2016), Jordan 46.39. In our study, the results revealed that infestation rate with *C. titillator* larvae in cold weather were higher than it was in the warm season. Moreover, all three stages of larvae were found in each month of the year. This indicates that the flies may be found in all seasons, but in various level of abundance. In comparison with our results, previous studies have shown that camel bot fly is more prevalent in cold season (Fatani and Hilali, 1994; Oryan *et al.*, 2008; Atiyah *et al.*, 2011). The flies hatch out mainly during the rainy and moist season but infection during other times of the year could not be excluded. According to the life cycle, it seems the small size of the first stage larvae that may be overlooked can be the reason for the low prevalence in warm seasons (Fatani and Hilali, 1994). Perhaps, the larvae migrate from their predilection site towards the nasal passage during the warm dry season ready to be expelled and pupate in the ground (Razi Jalali *et al.*, 2016). Furthermore, the present study showed that level of infestation with *C. titillator* larvae in females (56.6%) is higher than males 37.36%, these results indicate that the sex is a significant factor that affecting the prevalence of infestation with *C. titillator* larvae and agreed with several studies (Bekele, 2001and Atiyah *et al.*, 2011), and disagreement with (Oryan *et al.*, 2008) who reported that the percentage of infection is occurred in males 65 % is higher than in females 45.6%. The different susceptibility of *C. titillator* larvae between males and females may be due to the levels of sex hormones (Roberts *et al.*, 2001 and Atiyah *et al.*, 2011). The breeding system may play an important role in the exposure variation of males and females because of most of the females used for the purpose of pregnancy and reproduction which could decrease resistance in females besides the

lactation period, which are associated with hormonal and immunological changes. Whereas most of the males used for hard work and racing in many countries (Bekele, 2001; Kassa, 1995 and bassiony *et al.*, 2005).

In addition, the present study showed that the high percentage of infection with *C. titillator* larvae occurs in age group 4- 7 years in 65.61%. Whereas, lower percentage of infection is occurred in age group 8 months to 2 years old in 22.95%. The results were in agreement with many previous studies (Abul-Hab, *et al.*, 1977; Bekele, 2001 and Oryan, *et al.*, 2008). The difference in the distribution of infection with *C. titillator* larvae among age groups of study are explained by the camels of the group less than 2 years old were younger than a year and it is possible that they were born after the active season of the flies and were not exposed to infestation up to that time (Oryan, *et al.*, 2008). Furthermore, the continuous exposure of these camels to the adult fly led to make the old camels more susceptible to be infested with *C. titillator* larvae than younger camels. All of that resulted in slowing down its movement and then their inability to put the first larvae that is newly developed by the adult fly through sneezing or because of immunosuppression caused by progressive age (Atiyah *et al.*, 2011). Serum protein electrophoresis test has low specificity in the diagnosis, measuring the normal serum protein electrophoresis patterns in all domestic animals and the correct interpretation of their results is very useful for the clinician in diagnosing healthy and infected animals (Lutz *et al.*, 2009). The results of our study indicate that levels of α 1-globulins, α 2-globulins, β -globulins and γ -globulins were statistically significant increase in camels suffering from parasitic infection compared to healthy. The results were in agreement with many studies (Alberghina *et al.*, 2010, Piccione *et al.*, 2011 and Tóthová *et al.*, 2013). Serum protein electrophoresis standard method for fractionation and quantification of serum proteins is electrophoresis in clinical biochemistry. In conclusion, camels play an important role in the epidemiology of parasitic diseases under the three aspects of animal health, transmission to other livestock and zoonoses. Parasitic infections of camels may cause reduced milk and meat production, impaired fertility and decreased calving rates. They may also lower the working efficiency or even result in death and consequently high economic losses. The present work reflects the current state of knowledge on the parasitic fauna of camels in clinical, immunological and epidemiological studies on the parasites of camels in Al-muthanna province. Serum protein electrophoresis and determination of absolute values of serum protein fractions in dromedary camels by cellulose acetate electrophoresis is very useful for clinicians to diagnose and evaluate various pathological conditions. The results presented in this study showed a significant effect of parasitic infection on the concentrations of some of the serum protein fractions in camels.

References

Abd El-Rahman SS (2010). Prevalence and Pathology of Nasal Myiasis in Camels Slaughtered in El-Zawia Province- Western Libya: with a Reference to Thyroid Alteration and Renal Lipidosis. *Global Vet.* 4 (2): 190-197.

Abul-Hab J, Al-Affass NN (1977). Seasonal occurrence of the domestic camel botfly *Cephalopina titillator*, *Diptera*, *Oestridae* in central Iraq. Bulletin of the Bio. Research centre (Baghdad) 8:97-104.

Alahmed AM (2002). Seasonal prevalence of *Cephalopina titillator* larvae in camels in Riyadh Region, Saudi Arabia. Arab Gulf J. Sci. Res. 20(3): 161-164 .

Al-Ani F, Amr Z (2016). Seasonal prevalence of the larvae of the nasal fly (*Cephalopina titillator*) in camels in Jordan. Rev. Elev. Med. Vet. Pays Trop. 69 (3): 125-127. <https://doi.org/10.19182/remvt.31196>

Atiyah W, Dawood K, Dagher A (2011). Prevalence of infestation by camel nasal myiasis fly larvae in Al-Diwania city abattoir. Al-Qadisia J. Vet. Med. Sci. 2:20–26.

Bassiony GME, Al Sagir OA, El daly ES, El Nady AM (2005). Alterations in the pituitary –Thyroid axis in *Camelus dromedaries* infected by larvae of nasal bot fly *Cephalopina titillator*. J. Mnim. Vet. Adv. 4(3):345-348

Bekele T (2001). Studies on *Cephalopina titillator*, the cause of „Sengale, in camels (*Camelus dromedaries*) in semi-arid areas of Somali state, Ethiopia. Trop. Anim. Hlth. Prod. 33:489-500. <https://doi.org/10.1023/A:1012780512994>

Bekele M (2010). An Epidemiological Study on Major Camel Diseases in the Borana Lowland, Southern Ethiopia. DCG Report No. 58, Drylands Coordination Group, Oslo. pp. 67-98.

Borji H, Razmi G, Movassaghi AR, Naghibi AG, Maleki M (2010). A study on gastrointestinal helminthes of camels in Mashhad abattoir, Iran. Iran J. Vet. Res. 11:174–179.

Fatani A, Hilali M (1994). Prevalence and monthly variations of the second and Third instars of *Cephalopina titillator* (*Diptera: Oestridae*) infesting camels (*Camelus dromedarius*) in the Eastern Province of Saudi Arabia. Vet. Parasitol. 53: 145-151. [https://doi.org/10.1016/0304-4017\(94\)90026-4](https://doi.org/10.1016/0304-4017(94)90026-4)

Higgins AJ (1985). The camel in health and disease. Brit. Vet. J. 141: 197-216. [https://doi.org/10.1016/0007-1935\(85\)90153-8](https://doi.org/10.1016/0007-1935(85)90153-8)

Hussein M, Elamin F, El-Taib N, Basmaeil S (1982). The pathology of nasopharyngeal myiasis in Saudi Arabian camels (*Camelus dromedarius*). Vet. Parasitol. 9:179–183 . [https://doi.org/10.1016/0304-4017\(82\)90060-7](https://doi.org/10.1016/0304-4017(82)90060-7)

Kassa D (1995). Camel cephalopsis: Epidemiology and biodynamic in dromedary of eastern Ethiopia, DVM thesis, Faculty of veterinary medicine ,Addis Ababa University.

Morsy T, Aziz A, Mazyad S, Al Sharif K (1998). Myiasis caused by *Cephalopina titillator* (Clark) in slaughtered camels in Al Arish Abattoir, North Sinai governorate, Egypt. *J. Egypt Soc. Parasitol.* 28:67–73.

Musa MT, Harrison M, Ibrahim AM, Taha TO (1989). Observation on Sudanese camel nasal myiasis caused by the larvae of *Cephalopina titillator*. *Revue d'Elevage et de Med. Vet. des Pays Tropicaux.* 42(1): 27-31.

Oryan A, A Valinezhad, M Moraveji (2008). Prevalence and pathology of camel nasal myiasis in eastern areas of Iran. *Trop. Biomed.* Apr. 25(1): 30-6.

Otranto D (2001). The immunology of myiasis: Parasite survival and host defense strategies. *Trends Parasitol.* 17 (4): 176- 182. [https://doi.org/10.1016/S1471-4922\(00\)01943-7](https://doi.org/10.1016/S1471-4922(00)01943-7)

Radostitis OM, Blood DC, Gay CC (2000). *Vet. Med.* 9th Ed. Baieller, Tindal & Cox.Pp: 1034-1051.

Ramadan M (1997). Studies on some ectoparasites of camels. PhD thesis. Faculty of Veterinary Medicine, Zagazig University, Benha Branch, Egypt.

Razi Jalali MH, Dehghan S, Haji A, Ebrahimi M (2016). Myiasis caused by *Cephalopina titillator* (*Diptera: Oestridae*) in camels (*Camelus dromedarius*) of semi-arid areas in Iran: distribution and associated risk factors. *Comp. Clin. Pathol.* <https://doi.org/10.1007/s00580-016-2246-9>

Roberts CW, Walker W, Alexander J (2001). Sex – associated Hormones and immunity to protozoan parasites. *Clin. Microbiol. Rev.* 14(3):476–488. <https://doi.org/10.1128/CMR.14.3.476-488.2001>

Sazmand A, Joachim A (2017). Parasitic diseases of camels in Iran – a literature review. *Parasite.* 24, 21. <https://doi.org/10.1051/parasite/2017024>

Shakerian A, Hosseini S, Abbasi A (2011). Prevalence of *Cephalopina titillator* (*Diptera: Oestridae*) larvae in onehumped camel (*Camelus dromedarius*) In Najaf-Abad, Iran. *Global Vet.* 6:320–323.

Smith BP (1996). *Large Animals Internal Medicine.* New York , 2nd .ed .Mosby . Pp; 441, 473,498.

Zumpt F (1965). Myiasis in man and animals in the old-world. Butter Worths, London, XV: 267 pp.